

Elbow Passive Motion Rehabilitation Utilizing a Continuous Passive Motion Device following Surgical Release, Manipulation Under Anesthesia, or Post Stable Fracture: A Review

Edward Schuster OTR, MS

ABSTRACT

Background

Post-operative rehabilitation of the elbow following a stable fracture, surgical release or manipulation under anesthesia consists of a period of passive motion (PM) to prevent adhesions, the detrimental effects of immobilization, reduce pain, reduce inflammation and increase range of motion to a functional level. Continuous passive motion (CPM) devices have been used routinely as a PM modality.

Objectives

To determine, with evidence from peer-reviewed journals, the optimal rehabilitation strategy, including the use of CPM, after a release of a contracted or stiff elbow joint.

Search strategy

The search included MEDLINE (1980 to 2005), JBJS (1974 to 2005), AJSM, Sage Publications (1976 to 2005), Lippincott Williams & Wilkins online journals, Springerlink.com online journals, NCBI.nlm.nih.gov (database), elsevier.com (Elsevier Health Science Periodicals) and reference lists of articles.

Selection criteria

All peer-reviewed clinical studies for rehabilitation that included a CPM device after a surgical release or a manipulation under anesthesia for a contracted elbow joint.

Main results

Twenty-four studies following a release of a contracted joint were included. Data were not pooled. In all studies, CPM demonstrated either statistically significant (7 studies) or positive functional (17 studies) outcomes for subjective and objective measures. The outcomes evaluated were overall function, range of motion, compliance soft tissue healing, and cost effectiveness. CPM was superior to physical therapy alone, contracture splinting alone, or patient directed home exercises. The most often reported CPM duration was six weeks in order to achieve statistically significant results.

Author's conclusions

CPM regimens are widely employed in elbow rehabilitation after a fracture surgical release or a manipulation under anesthesia of a contracted joint and ligament repair. This review found sufficient evidence from peer-reviewed clinical studies that rehabilitation programs including CPM result in a net health benefit compared to programs with out CPM.

POST-OP CPM FOLLOWING ELBOW JOINT SURGICAL RELEASE, MUA OR STABLE FRACTURE

INTRODUCTION

CPM after the surgical release of a joint contracture has been used extensively in the elbow.⁶⁰ Clinical studies have demonstrated that CPM alone, CPM compared to splinting alone or CPM combined with physical therapy have resulted in superior statistical outcomes over programs without CPM.^{4,13,14,35,41,52}

The initial goal of therapy following a surgical release of a contracted joint is to maintain the range-of-motion gained after the release. If passive motion is not started within the first 48 hours following the release, the prognosis for improvement is significantly diminished.¹³ O'Driscoll and Giori⁹³ have demonstrated that CPM immediately following a surgical release acts to pump blood and edema fluid out of the joint and periarticular tissues. The reduction of these fluids from a synovial joint reduces the risk of post-surgical joint stiffness. A contracted joint typically has an inflammatory component which can be aggravated by the surgical release itself resulting in limited or no improvement in range-of-motion following the surgical procedure. Salter,¹²² Kim,⁵⁶ Kreder⁵⁹ and Moran⁸² have all shown that CPM has reparative effects on inflamed joints. However, until recently the mechanism by which CPM acts as an anti-inflammatory agent was unknown. Recent studies by Gassner,⁴⁰ Lee,⁶³ Xu¹⁴⁴ and Ferretti³³ have helped explain the molecular basis for the beneficial effects of CPM on the inflamed joint. A CPM device by applying cyclic tensile stress on the involved joint for an extended time counteracts the effects of the inflammatory agents even better than immobilization.

The efficacy of CPM following a joint release in the elbow is clearly demonstrated in the following peer-reviewed studies. CPM leads to greater functional outcomes, greater ROM, improved healing by acting as an anti-inflammatory agent and higher patient satisfaction. The duration of CPM use is determined by the severity of the contracture and as long as improvements are seen.

HOME EXERCISE COMPLIANCE

Compliance is a critical concern that limits the effectiveness of patient self-directed exercise. Milroy⁷⁹ (Figure 1) in a review of studies on home rehab exercise compliance found as many as

Milroy et al

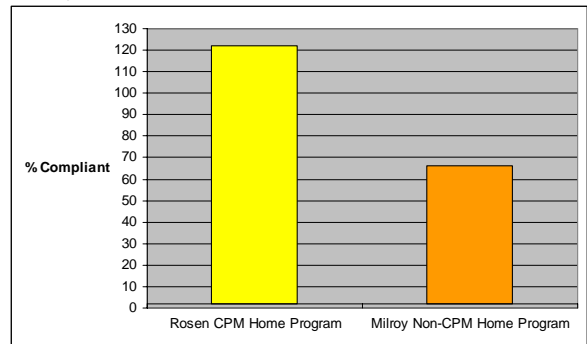


Figure 1
Comparison of home compliance of CPM versus other home exercise programs. CPM compliance is higher due to the pain reduction and anti-inflammatory properties associated with CPM use.

one-third of all patients fail to follow through with their prescribed regimen and as many as two-thirds only partially follow through. In contrast continuous passive motion compliance is high.

Rosen et al¹⁰⁶ found a 122% compliance rate for the CPM group as participants utilized the CPM device 7.3 hours on average, which was higher than the requested 6 hour rate. High compliance for home CPM use following a rotator cuff repair has been reported by both Royer¹⁰⁷ and LaStayo.⁶² Kinex Medical²² reported a 98% compliance rate for 100 users of shoulder CPM following rotator cuff repair surgery.

Shoo et al¹²⁷ reported in a study on the influence of home exercise performance that "the small number of existing studies show that the greater number of adherence to an exercise program is associated with reduced pain".

LaStayo et al⁶² (Figure 2) reported a statistically significant reduction in pain with shoulder CPM compared to manual passive range of motion following rotator cuff repair ($p=0.046$). Raab et al⁹⁸ also found a statistically significant reduction in pain in the shoulder CPM group compared to the patient-directed group and physical therapy assisted group post rotator cuff surgery ($P=0.0185$).

LaStayo et al

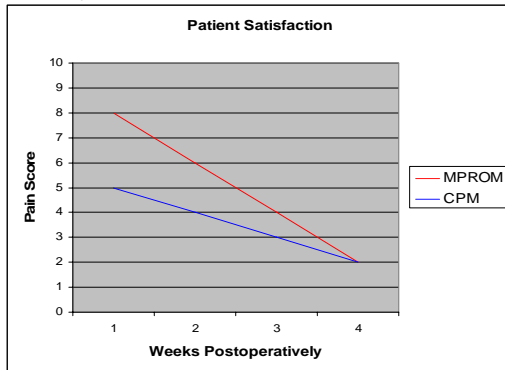


Figure 2
CPM offers a statistically significant reduction in pain post-op compared to physical therapy following shoulder surgery (0=low pain and 10=high pain).

High compliance with CPM in the home compared to patient self-directed exercise can be explained by the pain reduction properties of CPM.^{19,29,62,75,102,107,145}

PEER-REVIEWED STUDIES ON THE USE OF ELBOW CONTINUOUS PASSIVE MOTION

A search in peer-reviewed medical journals for clinical studies involving the use of continuous passive motion following the release of a contracted elbow joint revealed twenty-four studies. In all studies the use of CPM for passive motion following a surgical joint release, burn or stable fracture resulted in both objective and subjective positive outcomes for overall function, range of motion, compliance and cost effectiveness.^{4,8,10,12,35,41,52,60,85,99,100,126,136} Post-operative rehabilitation protocols that included CPM are proven to be statistically more effective than protocols that did not include CPM (compared to physical therapy alone, splinting alone, or patient directed exercises).^{4,13,35,41,52,126}

1. Aldridge JM, Atkins T, Gunnerson EE, Urbaniak JR; Anterior release of the elbow for extension loss. *J Bone Jt Surg 86A* (9):1955-60, 2004.

The purpose of this study was to report the outcomes of surgical correction, predominantly with an anterior release, of elbow flexion contractures. In addition, the author's evaluated the efficacy of continuous passive motion for four weeks or more depending on the severity of the contracture. The author's retrospectively reviewed the

outcomes of 106 consecutive patients who had undergone anterior elbow release for the treatment of a flexion contracture between July 1975 and June 2001. Twenty-nine patients were excluded because they had been followed for less than 12 months, leaving a study group of 77 patients. Post-operatively, 54 of the 77 patients were treated with continuous passive motion and the other 23 patients were treated with extension splinting. The average duration of follow-up was 33 months. The average patient age was 34 years. The results were evaluated on the basis of both pre-operative and post-operative radiographs as well as clinical measurements of elbow motion, all performed by the same examiner using the same large (47-cm-long) goniometer.

Results: The mean pre-operative extension in the 77 patients was 52°, which decreased to 20° post-operatively. The mean flexion increased from 111° pre-operatively to 117° post-operatively, and the mean total arc of motion increased from 59° to 97°. The total arc of motion in the patients treated with continuous passive motion increased 45°, compared with an increase of 26° in those treated with extension splinting (P=0.27).

Compared with contractive splinting in extension alone, the utilization of continuous passive motion during the post-operative period resulted in a statistically significant increase in the total arc of motion (Figure 3).

Aldridge et al

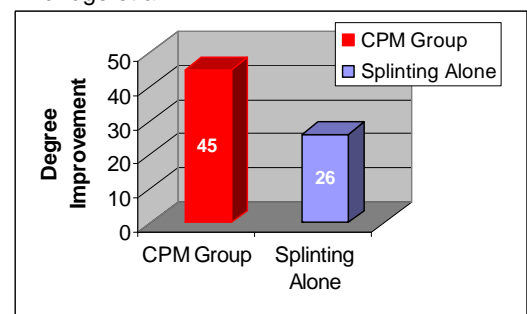


Figure 3
CPM following a surgical release offers statistically superior functional outcomes over splinting and physical therapy without CPM. (p=0.27)

2. Ippolito E, Formisano R, Caterini R, Farsetti, P, Paneta F: Resection of elbow ossification and continuous passive motion in postcomatose patients. *J Hand Surg.* 24A(3): 546-53, 1999.

Heterotopic periarticular ossifications were surgically excised in 16 elbows of 14 traumatic brain injury patients an average of 18.9 months (range, 4-67 months) after the end of a coma. In 11 elbows the ulnohumeral joint was ankylosed in a position that ranged from 0° to 100° of flexion (Group 1); in five elbows the arc of flexion ranged from 10° to 25° (Group 2). Full pronation and supination were present in 15 of the elbows; in one the radiocapitellar joint was fixed at 30° of pronation by a partial ossification of the interosseous membrane. The arc of flexion attained after surgery averaged 115° (range, 90° to 145°) in the Group 1 elbows and 128° (range, 115° to 140°) in the Group 2 elbows. In an attempt to prevent post-operative loss of motion and recurrence of ossification, continuous passive motion was applied to the affected elbow for six weeks before starting a fully active rehabilitation program. All the patients were examined at regular intervals after the surgery. The follow-up period ranged from 12 to 60 months (average, 30.7 months). During the follow-up period, all the elbows showed improvement in range of motion and the arc of flexion averaged 95° (range, 30° to 135°) in the group 1 elbows and 116° (range, 80° to 145°) in the Group 2 elbows.

The authors compared their results to several other authors who did not utilize CPM following a similar series. CPM was identified as an important factor that resulted in superior results.

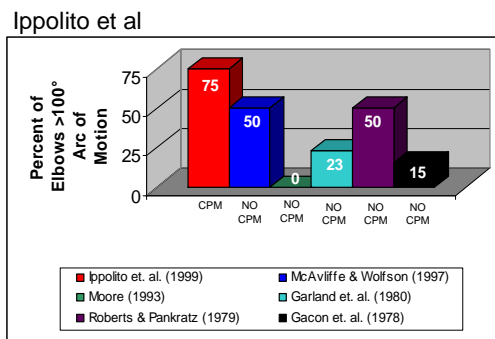


Figure 4 CPM is a more effective in reaching functional ROM then a rehab program with out CPM following the release of a stiff joint.

The author's results were superior with CPM when compared to previous investigators who did not use CPM for six weeks postoperatively (Figure 4).^{36,37,70,81,103}

3. Gates H, Sullivan F, Urbaniak J: Anterior capsulotomy and continuous passive motion in the treatment of post-traumatic flexion contracture of the elbow; A prospective study. *J Bone Jt Surg* 74A(8): 1229-39, 1992.

Thirty-three patients who had a post-traumatic flexion contracture of the elbow were managed consecutively with anterior capsulotomy without tenotomy of the biceps tendon or myotomy of the brachialis muscle. The first 15 patients (Group 1) did not receive continuous passive motion post-operatively. Pre-operative active extension for Group 1 was an average of 48° short of full extension, which improved to 19° at a mean follow-up time of 45 months. Subsequently, 18 patients (Group 2) received continuous passive motion post-operatively for a mean of six weeks. Pre-operative active extension for Group 2 was on average 55° short of full extension, which improved to 23° at a mean duration of follow-up of 35 months. The mean pre-operative arc of motion for Group 2 was 69°, which improved to 94° postoperatively. The mean preoperative arc of motion for Group 2 was 48°, which improved to 95° postoperatively. Five patients in Group 1 and six patients in Group 2 had severe pre-operative heterotopic ossification (Figure 5).

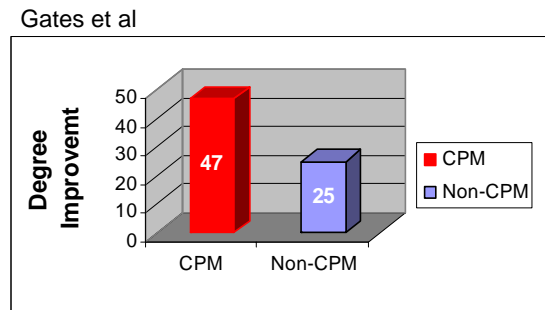


Figure 5 CPM for 6 weeks post-op resulted in a statistically significant improvement in function.

The use of CPM on average for six weeks post-operatively improved the total arc of motion following an anterior capsulotomy by 47° compared to 25° for the non-CPM group. The difference between the groups was statistically significant.

4. Olivier LC, Assenmacher S, Setareh E, Schmit-Neverborg KP: Grading of functional results of elbow joint artholysis after fracture treatment: Arch Orthop Trauma Surg. 120:562-569, 2000.

In the treatment of post-traumatic contracture of the elbow joint, artholysis is a proven procedure. A total of 91 patients with artholysis of the elbow could be followed-up on average of 44 months (range 9-102 months) after operative (58, 63.7%) and non-operative (33, 36.3%) fracture treatment. The mean pre-operative range of motion (ROM) in flexion/extension was 49° (SD ± 38°), while in pronation/supination it was 89° (SD ± 66°). Post-operatively, the ROM was on average 94° (SD ± 27°) in flexion/extension and 129° (SD ± 52°) in pronation/supination. Using our own grading system, it became evident that most patients had a functional benefit from the procedure, although the quality of the improvement differed. For example, postoperatively 59.3% of the patients were grade I (90° in flexion/extension compared with 16.5% preoperatively (Figure 6).

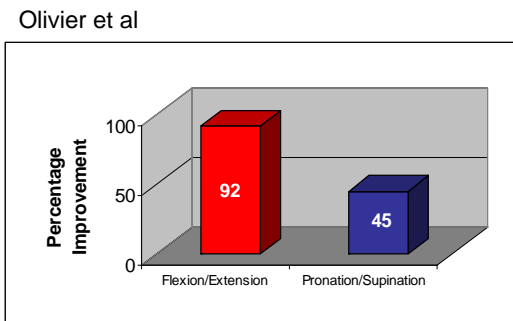


Figure 6
The use of CPM following a stable fracture both operative and non-operative resulted in statistically significant improvement following the surgical release of a joint (p< 0.05).

The earlier the release of the elbow joint; the better was the functional outcome (p < 0.05). The importance of an intensive early continuous passive motion program is emphasized while indication for this procedure should only be seen in compliant patients.

5. Wu CC: Post-traumatic contracture of the elbow treated with intra-articular techniques; Arch Ortho Trauma Surg 123(9): 494-500, 2003.

Post-traumatic contracture of the elbow is very disabling. However, an absolutely convincing surgical technique has not been defined in

the literature. We developed an intra-articular technique to concomitantly treat both intra-articular and extra-articular lesions with one posterior incision. Twenty consecutive adult patients were treated with anteroposterior capsule release. Immediately postoperatively, continuous passive motion was initiated. All 20 patients were followed up for median of 3.8 (range 2.1-2.2) years. The satisfactory rate was 95% (19 of 20, p<0.001). The flexion contracture improved from an average of 42° to 13° which was statistically significant (p<0.001), and maximal flexion improved from an average of 89° to 131° (p<0.001). The arc of motion improved from an average of 47° to 118° (p<0.001). The sole unsatisfactory patient still had 20°-110° arc of motion. There were no evident complications noted (Figure 7).

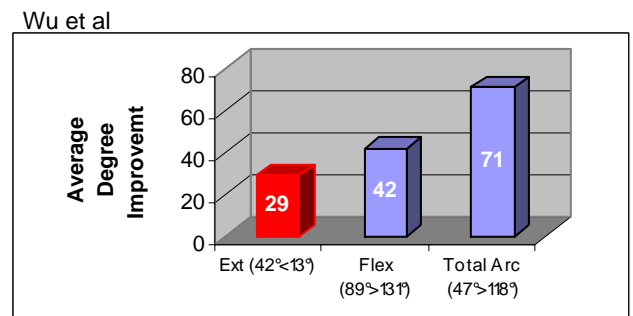


Figure 7
Statistically significant improvements were researched due in part to the use of CPM post fracture.

This surgical technique followed by the use of early CPM resulted in a high satisfaction rate, a low complication rate, and a statistically significant improvement in ROM.

6. Bae DS, Waters P: Surgical treatment of post-traumatic elbow contracture in adolescents. J Ped Ortho 21(5): 580-584, 2001.

Thirteen adolescent patients with post-traumatic elbow contractures were treated with open surgical release at an average of 16.2 years of age. When possible, an extensile medial approach to the elbow was used. All patients were treated with six weeks of postoperative continuous passive motion. Eleven patients with >6 months of follow-up were evaluated at an average of 29 months after surgery. Average loss of extension improved from 57° to 15°, and average flexion improved from 109° to 123°. Average total arc of motion improved from 53° to 107° (Figure 8).

Bae et al

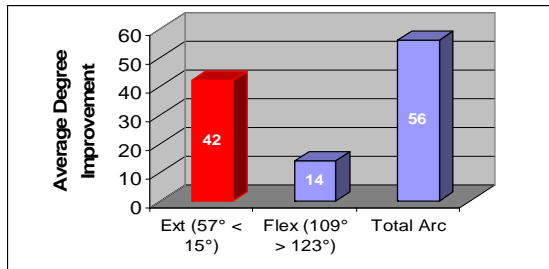


Figure 8
The CPM grouped reached the functional ROM level of 100° more often compared to the non-CPM group which did not reach the functional ROM level as often.

A significant finding by the author is that functional ROM was reached (greater than a 100° arc) on average with the use of CPM post-operatively for 6 weeks.

7. Phillips B, Strasburger S: Arthroscopic treatment of arthrofibrosis of the elbow joint. J Arthro Rel Surg 14(1), 1998.

Twenty-five patients with arthrofibrosis of the elbow were treated with arthroscopic debridement followed by post-operative use of CPM; 15 had post-traumatic arthrofibrosis and 10 had contractures caused by degenerative arthritis. At an average follow-up of 18 months, all patients had increased motion and decreased pain. Patients with post-traumatic arthritis had more severe flexion contractures pre-operatively than did those with degenerative arthritis, but they also had more improvement post-operatively (Figure 9).

Phillips et al

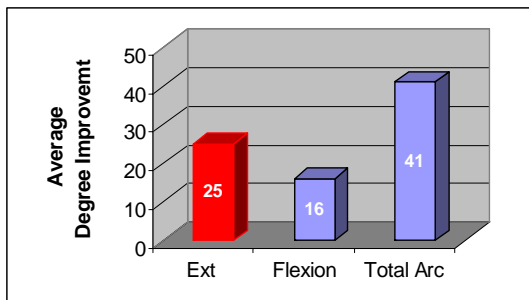


Figure 9
ROM improvements were statistically superior to protocols that did not use CPM post-operatively.

Arthroscopic release and debridement of arthrofibrotic elbow joints followed by the use of CPM obtained improvements equal to that obtained by open techniques, with less morbidity and

earlier rehabilitation. Range-of-motion improvements were statistically significant (P=0.001).

8. Breitfus H, Muhrg G, Neuman K, Rehn: Arthrolysis of post-traumatic stiff elbow; Which factors influence the end result. Unfallchirurg 94(1):33-9, 1991.

The results obtained with elbow arthrolysis performed for the treatment of post-traumatic stiffness were analyzed via a retrospective study of 59 patients. The intra-operative functional result was classified as excellent in all cases, while on average 27 months after the operation the range of movement was decreased again to varying extents. This deficit correlated with the type of injury, timing of arthrolysis, duration of metal implants and timing and type of post-operative rehabilitation program. The relative increase in function was better after simple fractures with 47%, than after fracture dislocations with 35%. After arthrolysis within three months of onset of posttraumatic stiffness, the range of improvement was 55%, compared with an increase of only 30% after 10 months' stiffness. When arthrolysis was combined with metal removal and the implants had been in place for longer than 9 months, the increase achieved was only 15%. Patients started on CPM on the first day post-operatively lost only 15% of their intra-operative function. If CPM was delayed to between the second and fifth day, 30% was lost. Utilizing a splint program for maximal joint flexion and extension at four-hour intervals instead of CPM resulted in a 35% loss of range of movement postoperatively. In contrast there was a loss of only 17% in the group with combined physiotherapy and continuous passive motion (Figure 10).

Breitfus et al

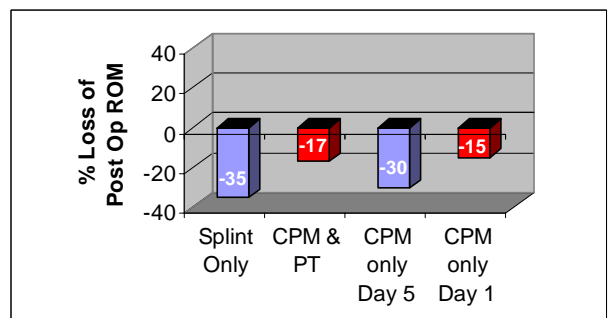


Figure 10
Statistically superior results were obtained when CPM was applied within 48 hours compared to a delayed application. Even delayed CPM use was superior to non-CPM protocols.

The results show that the prognosis of elbow arthrolysis is determined by early mobilization with a CPM device and optimal operative planning. The time to arthrolysis should be as short as possible, as should the time to removal of metal implants. The aim of the rehabilitation program is immediate postoperative continuous passive motion.

9. Schindler A, Yaffe B, Chetrit A, Modan M, Engel J: Factors influencing elbow arthrolysis. *Ann Chir Maine Super* 10(3): 237-42, 1991.

Over the period 1982 to 1988, 31 consecutive patients at the Hand Surgery Unit of the Sheba Medical Centre were subjected to elbow joint arthrolysis to treat restriction of range of motion solely due to trauma. This retrospective study aims to evaluate the relative influence of the following factors on functional outcome: sex, age, type of original injury and initial management, presence of para-articular ossification, delay between injury and arthrolysis, and the use of manipulation and a continuous passive motion device (CPM) following surgery. The range of motion was recorded prior to arthrolysis and after operation (excluding one patient who subsequently underwent arthrodesis for intractable pain). Follow-up averaged 15.3 months (± 5.4). In the 24 patients with extension deficit ($>20^\circ$), the mean improvement was of 26.9° ($>23.1^\circ$); in the 21 patients with flexion deficit the mean improvement was 21.2° ($>18^\circ$). The mean improvement for total range of motion in the series overall was 35.2° ($\pm 23.8^\circ$). Ninety percent showed an improvement of at least 10° and 30% attained normal ROM. All of these improvements in range were statistically significant ($p < 0.0001$) (Figures 10 and 11).

Schindler et al

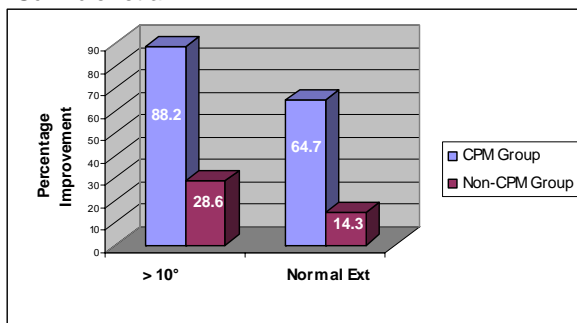


Figure 11
The CPM group reached functional ROM more often than the non-CPM group and the difference was statistically significant at ($p < 0.001$).

“With regard to improvement in extension, the only variable of value was the use of a continuous passive motion device following surgery; those patients subjected to CPM showed a mean improvement of 32.6° ($\pm 19.0^\circ$), while those without averaged 12.8° ($\pm 27.5^\circ$) ($p < 0.01$). Respective rates of improvement beyond 10° were 88.2% (CPM) vs. 28.6% (non-CPM) while the respective incidences of patient attaining normal extension were 64.7% (CPM) vs. 14.3% (non-CPM) at $p = 0.03$ (Figure 12).

Schindler et al

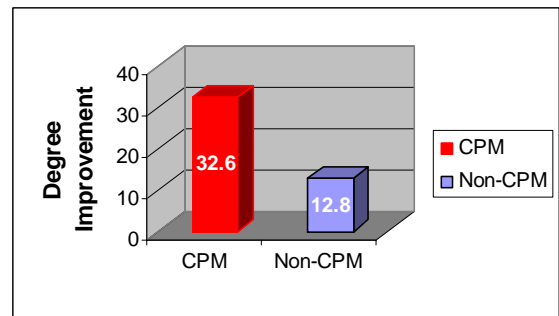


Figure 12
The CPM device was the only variable that demonstrated a statistically significant improvement in ROM.

10. Tsionos, I, Leclercq C, Rochet JM: Heterotopic ossification of the elbow in patients with burns: Results after early excision. *J Bone Joint Surg Br* 86-B:396-403, 2004.

Heterotopic ossification which may develop around the elbow in patients with burns may lead to severe functional impairment. We describe the outcome of early excision for heterotopic ossification undertaken as soon as the patient's general and local condition allowed. The mean age at operation was 42 years. The mean area of burn surface was 40%. The mean pre-operative range-of-motion (ROM) was 22° in flexion/extension and 94° in pronation/supination. The mean time between burn and surgical release was 12 months with a median of 9.5 months. The mean follow up period was 21 months (Figure 13).

Between 1992 and 2001, a consecutive series of 28 patients with 35 elbow burns underwent a surgical release due to heterotopic ossification. All procedures were performed by the same surgeon followed by continuous passive motion (CPM) starting on the sec-

Tsionos et al

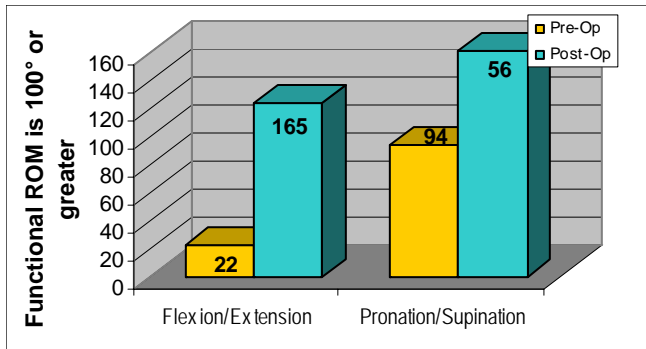


Figure 13
Early excision of elbows with heterotopic ossification following a severe burn is recommended to reach functional ROM.

ond postoperative day. The CPM was used for eight hours a day for three to four weeks with diminished daily use for another two to four weeks for a total of five to eight weeks. The CPM device was used as needed to gain ROM or to preserve ROM gained from the surgical release.

The gains in ROM were statistically significant improving from a mean of 22° to 123° in flexion/extension and a mean of 94° to 160° in pronation/supination. The improvement in ROM reached 100° in the total flexion/extension arc and 100° in the pronation/supination arc which is considered the minimum to perform most daily activities. The authors conclude that early excision of elbows with heterotopic ossification following a severe burn followed by CPM is recommended to reach functional ROM.

11. Breen TF, Gelberman RH, Ackerman GN: Elbow Flexion contractures; treatment by anterior release and continuous passive motion. *J Hand Surg 13B:286, 1988.*

The authors reported a series of patients with post-traumatic flexion contractures who did not respond to non-operative physical therapy, dynamic splinting or a bracing program. The average flexion contracture was 41°. The patients underwent an anterior surgical release followed by continuous passive motion (CPM) immediately post-op in the hospital with continuation in the patients' home. Full extension was achieved in the operating room. At a 12 month follow-up the patients improved to a mean of a 5° flexion contracture.

The authors compared their results with a similar series from Urbaniak et al who did not use CPM post-operatively and reported a flexion contracture of 19° (CPM).

This series was a preliminary study on the efficacy of elbow CPM demonstrating superior positive results compared to a similar series by Urbaniak et al (1985) who did not use CPM postoperatively. "Our results indicate that improvements over standard methods of rehabilitation (splinting, physical therapy) after capsular release can be achieved with this technique (CPM).

12. Oka Y: Debridement arthroplasty of osteoarthritis of the elbow; 50 patients followed a mean of 5 years. *Acta Orthop Scand 71(2): 185-190, 2000.*

The characteristics and surgical outcome of debridement arthroplasty were investigated in athletes and manual laborers with osteoarthritis of the elbow. There were 26 elbows in athletes, and 24 elbows in laborers. The mean age was 32 years in athletes and 50 years in laborers. The osteoarthritis was mainly mild in athletes, but moderate or severe in laborers. Debridement arthroplasty, consisting of resection, osteophytes and removal of loose bodies, was performed in all cases followed by the use of continuous passive motion (CPM). Surgery followed by the use of CPM relieved pain and improved range of motion at an average follow-up of 59.5 months. Evaluation of the long-term outcomes at more than five years showed recurrence of mild osteoarthritis with minimal symptoms.

Debridement arthroplasty followed by the use of CPM post-operatively is an effective treatment in athletes and manual laborers with osteoarthritis of the elbow. The mean average increase was 24° with no difference in improvement between athletes or laborers.

13. Husband JB, Hastings H: The lateral approach for operative release of post-traumatic contracture of the elbow. *J Hand Surg 72(9):1353-8, 1990.*

A lateral approach was used to release a post-traumatic contracture of the elbow in seven patients followed by the use of continuous passive motion (CPM) post-operatively. The results were evaluated an average of 38 months post-operatively. Extension

improved from an average flexion contracture of 45° pre-operatively to 12° post-operatively and the average point of maximum flexion increased from 116° pre-operatively to 129° post-operatively. The average arc of motion increased 46°.

A lateral release is an effective surgical option following an elbow contraction with the use of CPM post-operatively.

14. Blauth M, Haas MP, Sudkamp NP, Happe T: Arthrolysis of the elbow in post traumatic contracture. *Orthopade* 19(6): 332-342, 1990.

Intra- and peri-articular fractures about the elbow joint are treated with open reduction and internal fixation. This allows early function after treatment. Nevertheless, the range of motion remains more or less unsatisfactory. In these cases open arthrolysis provides a considerable improvement in joint function. We therefore recommend this operation when the hardware is removed after the accident. The reasons for post-traumatic contracture of the elbow could be intrinsic such as interposed fragments, intra-articular adhesions, incongruity of the articular surfaces--or extrinsic—like contractures of the capsule and ligaments, adhesions of different layers, ectopic bone formations.

An individually modified rehabilitation program is as important as the operative procedure itself to achieve the best results possible. Physiotherapy is supported by CPM machines as early as possible. Patients must be prepared with the help of drugs and the application of ice bags. Even after months, improvement of motion can be obtained. In a retrospective follow-up study, 125 out of 168 patients with arthrolysis of the elbow joint were reviewed. Most patients sustained a fracture of the distal humerus. In 77%, the results were graded as very good, good, or satisfactory, i.e., the average relative improvement amounted to at least 40% according to the criteria of W. Blauth. Patients with very severe (preoperative ROM, 0-30°) and severe (preoperative ROM 30-60°) contractures profited more (relative improvement 60%) than the others (relative improvement 45%). Overall, the average arc of total motion increased 49° and the relative improvement of motion increased by 58%.

Arthrolysis followed by CPM demonstrated significant improvements in 125 patients who were reviewed by the author.

15. Remia LF, Richards K, Waters P: The Bryan-Morrey Triceps-Sparing approach to open reduction of t-condylar humeral fractures in adolescents; cybex evaluation of triceps function and elbow motion. *J Pediatric Orthop* 24(6): 615-619, 2004.

Nine patients who underwent open reduction of a T-condylar distal humerus fracture through a Bryan-Morrey triceps-sparing approach were evaluated for triceps function and elbow motion. The average follow-up was 3 years 5 months. The average range of motion was -8° to 136°. Compared with another study that tested triceps function after open reduction with the Campbell triceps-splitting approach, no statistically significant difference in function or range of motion was found. In this small series, early post-operative continuous passive motion was found to significantly increase range of motion. The Bryan-Morrey triceps-sparing approach can be used in children and adolescents who require open reduction of T-condylar distal humeral fractures.

In this series, early post-operative use of CPM was found to significantly increase range of motion.

16. Re PR, Walters PM, Hresko T: T-Condylar fractures of the distal humerus in children and adolescents. *J Pediatric Orthop* 19(3): 313-318, 1999.

This was a retrospective review of 17 T-condylar fractures in children and adolescents, aged 9-16 years. It examined the results by sex, age, arm injured, hand dominance, mechanism of injury, radiologic appearance, operative findings, operative procedure, outcome, and complications. There was a male-to-female ratio of 2.4:1. The large majority of patients received their fractures as a result of a fall. Fifteen patients underwent open reduction, internal fixation followed by the use of CPM, with a mean postoperative follow-up of 16 months. The posteromedial (Bryan-Morrey) and the olecranon osteotomy approach resulted in a statistically significant better extension than the triceps-splitting approach ($p < 0.05$). Patients with articular damage had statistically significantly less extension at follow-up ($p < 0.001$).

"The use of CPM in the immediate post-operative period resulted in a functional range of motion sooner and a statistically significant increase in flexion at follow-up exam compared to the group without CPM" ($p < 0.05$).

17. Letsch R, Schmit-Neveburg KP, Sturmer KM, Walx M: Intraarticular fractures of the distal humerus; surgical treatment and results. *Clin Ortho Rel Res* 241: 238-44, 1989.

In a 12-year period, 104 patients with intra-articular fractures of the distal humerus received surgical treatment. Based on the Arbeitsgemeinschaft für Osteosynthesefragen/Association for the Study of Internal Fixation (AO/ASIF) classification, there were 40 monocondylar fractures, 46 bicondylar fractures, and 18 fractures of the ulnar epicondyle with the fragment dislocated in the elbow joint. In children almost all fixations were done with Kirschner wires. The adult fractures were stabilized according to the recommendations of the AO/ASIF, i.e., monocondylar fractures by screws and /or single-plate fixation and bicondylar fractures by screws and dual-plate fixation, preferably with reconstruction plates. Comminuted fractures required an additional osteotomy of the olecranon. Except for children, the essential feature of post-operative management was early functional treatment by continuous passive motion. Eighty-eight patients (84.6%) were followed with an average follow-up time of 4.4 years. The results were evaluated for range of motion, pain, working capacity, neural and vascular impairment, valgus/varus deformity, and subjective judgment. The long-term outcome of almost 81% good and very good results suggests that operative treatment can be valuable when indications, anatomic surgical reconstruction, and postoperative care includes CPM.

The use of CPM post-operatively contributed to a 30% reduction in hospitalization time because home therapy was improved. The authors also report that the use of CPM decreased the incidence of myositis ossificans while improving ROM.

18. Sofer SR, Yahiro MA: Continuous passive motion after internal fixation of distal humerus fractures. *Orthop Rev* 19(1): 88-93, 1990.

Two patients with severe intra-articular fractures of the distal humerus were treated with internal fixation and postoperative continuous passive motion (CPM) of the elbow. The CPM machine's range of motion was initially set at 30° to 70° of flexion for one patient and 45° to 90° of flexion for the other. The arc of motion was gradually increased daily without discomfort. There was no occurrence of wound complications, nonunion, loss of reduction,

heterotopic ossification, or failure of fixation. At last evaluation, both patients had full pronation and supination. One patient had 0° to 135° of elbow flexion, and the other had 30° to 110°. Both patients had pain-free elbows. CPM was found to be a valuable therapeutic modality in the postoperative management of intra-articular fractures of the elbow.

The authors concluded in this early study that CPM was a valuable therapeutic modality in the post-operative management of intra-articular fractures of the elbow.

19. Chen W-S, Wang C-J, Eng H-L: Tuberculous arthritis of the elbow. *International Orthopaedics* 21(6):367-370, 1999.

Twenty-three patients with tuberculous arthritis of the elbow were treated and followed for three to eight years. The diagnosis was established by finding mycobacterium tuberculosis in the aspirate or in a surgical specimen in 18, and histology in five. A long history of symptoms and extensive involvement of bone and joint are associated with poor results. Early diagnosis and adequate treatment can be followed by good functional results. Post-operative continuous passive motion (CPM) is valuable in improving range of movement in elbows with extensive osteoarticular tuberculosis.

Early diagnosis and surgical treatment followed by CPM resulted in good functional outcomes in elbows with extensive osteoarticular tuberculosis.

20. Marti RK, Kerkhoffs G, Maas M, Blankevoort L: Progressive surgical release of a posttraumatic stiff elbow; technique and outcome after 2-18 years in 46 patients. *Acta Orthop Scand* 73(2): 144-150, 2002.

The authors treated 46 consecutive patients (47 elbows) suffering from post-traumatic contracture of the elbow joint with operative release. A lateral approach was used to perform a capsulectomy after release of the extensor muscles in 23 elbows. An additional medial approach was used to excise ulnar adhesions and perform a more extensive capsulectomy and an ulnar nerve neurolysis in 24 elbows. Post-operative rehabilitation consisted of immediate passive range of motion exercises utilizing a continuous passive motion (CPM) device. The results were assessed after a mean of 10 years.

Before surgery the mean active arc of motion was 45°, which im-

proved to 99°. The mean post-operative flexion was 114° and the mean extension lag was 15°. Pronation and supination improved from a mean of 8° before surgery to 98° after surgery. No patient suffered from joint instability, or an increase in pain. Forty-four patients were satisfied with the result at the latest follow-up. The authors found similar improvements in both surgical technique groups.

The authors reported that their rehabilitation program supported the findings of Gates et al (1992) that post-operative use of CPM improves total arc of motion and therefore improves function.

21. Kaczander B: The podiatric application of continuous passive motion; a preliminary report. *J Am Podiatr Med Assoc* 81 (12): 631-637, 1991.

This report is a preliminary review of the use of continuous passive motion (CPM) with the pediatric population. The authors report that CPM with this population prevents joint stiffness, reduces pain, stimulates the regeneration of articular tissue, eliminates adhesions and is well tolerated by younger patients. The development of CPM in animal as well as clinical studies are presented, especially following pediatric surgery.

Safety and the efficacy of CPM following surgery in the pediatric population is supported in this clinical review.

22. Cheng SL: Treatment of the mobile, painful arthritic elbow by distraction interposition arthroplasty. *J Bone Joint Surg* 82-B:233-238, 2000.

Between 1986 and 1994, 13 patients with mobile painful arthritic elbows were treated by distraction interposition arthroplasty using fascia lata. The mean period of follow-up was 63 months. An elbow distractor/fixator was applied for three to four weeks to separate the articular surfaces and to protect the fascial graft. Nine of the 13 patients (69%) had satisfactory relief from pain; eight (62%) had an excellent or good result by the objective criteria of the Mayo Elbow Performance score. Four have required revision to total elbow arthroplasty at a mean of 30 months with good results to date. Continuous passive motion (CPM) was instituted with in 48 hours after the procedure.

“Although less reliable than prosthetic replacement, distraction arthroplasty followed by CPM is a useful option in the treatment of young, high-demand patients with arthritis of the elbow. It is rarely indicated in the presence of generalized inflammatory arthritis, but may be of value in those patients in whom the disease is limited primarily to the elbow.”

23. Mileti's study (as cited in Gartsman GM, Hasan SS: What's new in shoulder and elbow surgery. *J Bone Joint Surg Am* 86: 189-202, 2004.

Mileti reported on osteocapsular arthroplasty, an arthroscopic procedure for the treatment of osteoarthritis that involves removal of loose bodies; resection of osteophytes in and around the olecranon, coronoid, and radial fossae; and release of capsular contractures. Continuous passive motion was used post-operatively up to six weeks. After a minimum duration of follow-up of one year, the mean total arc of motion improved from 76 to 124°, with flexion to 136° and an extension deficit of 12°. A functional arc of motion was achieved in 15 of 17 patients. Pain at the end of the range of motion, which had been moderate to severe in all patients pre-operatively, was eliminated in 13 patients.

CPM was found to be an effective rehabilitation tool in this study.

24. Tsuge K, Mizuseki: Dbridement of arthroplasty for advanced primary osteoarthritis of the elbow; results of a new technique used for 29 elbows. *J Bone Joint Surg Br* 76-B: 641-6, 1994.

The authors report on a new technique and results of a new method of debridement arthroplasty followed by the use of continuous passive motion (CPM) immediately post-op. Triceps and the periosteum of the olecranon are reflected towards the ulnar side and the joint is opened by dividing the radial collateral ligament. Osteophytes are removed, the olecranon and coronoid fossae are deepened and the fibrosed anterior joint capsule is excised. The degenerative changes are always more advanced on the radial side, with erosion of the capitellum, and it is necessary to remodel the head of the radius. In 29 elbows reviewed at a mean of 64 months, the average gain of range of motion was 34°, with good pain relief and improved grip in most patients.

CPM was a useful post-operative rehabilitation tool.

EFFICACY OF ELBOW CPM POST-SURGICALLY

Prior to 1989 there were few reports on the use of CPM following the surgical release of a joint contracture. Frykman³⁵ reported statistically superior outcomes ($p < .05$) on the use of CPM for stiff MP and PIP joints for posttraumatic ankylosis in 1989. CPM for six weeks in duration was tried after a vigorous hand therapy program had failed or after a previous surgical intervention without CPM had failed. Bradley¹² reported significant positive results with CPM use for 10 hours per day after arthroscopy and manipulation for primary adhesive capsulitis of the shoulder in 1991. Also in 1991, a retrospective study by Breitfus¹³ found CPM to be superior over physical therapy or splinting only program. The author also looked at start time and found superior results were seen when CPM was started within 48 hours following the surgical procedure. A second retrospective study was done by Schindler¹²⁶ between 1982-1988 and found CPM the only rehabilitation variable of value. CPM was initiated following an arthrolysis procedure for a contracted joint and resulted in a statistically significant improvement ($p < 0.01$) both in range of motion and function (88% of CPM users improved more than 10° while only 29% of non users had similar success).

A study by Gates⁴¹ in 1992 compared physical therapy to a CPM (six weeks) protocol following a release of a elbow joint contracture. The CPM group improved a mean of 47° compared to only 25° in the physical therapy group. Ippolito⁵² also reported functional improvements with elbow CPM after six weeks of use compared to a similar series who only utilized physical therapy in 1999. The importance of an intensive early CPM program was emphasized by both Olivier⁹⁹ and Bennet¹⁰ following elbow surgical releases in 2000. Olivier⁹⁹ had 91 patients and Bennet¹⁰ had 68 patients who reached statistically significant ($p < 0.05$) gains in range of motion and function after a capsulotomy and post op use of CPM. Aldridge⁴ compared the efficacy of elbow CPM to a traditional splinting program in 2004. Splinting programs following a surgical release of a stiff joint had been the standard of practice with many surgeons. This study of 106 joints joins the growing body of research demonstrating statistical superior results of elbow CPM ($p = 0.27$) over splinting and physical therapy only programs (Figure 14).

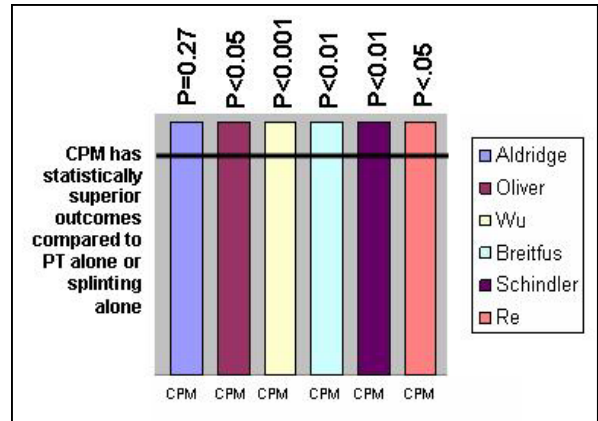


Figure 14
The use of early CPM resulted in statistically superior outcomes when compared to physical therapy only or combined splinting and physical therapy protocols without CPM.

The average period of use was six weeks following a surgical release or manipulation of the elbow in order to reach statistically significant improvements in range of motion and function (Figure 15). Only two authors out of 24 mentioned that they used CPM for four weeks or less. Actual duration typically depended on the patient's response to CPM. If the patient's range of motion stabilized (no increase or decrease) then CPM was reduced or discontinued. If a loss of motion was detected, or continued gains seen, then CPM was continued.

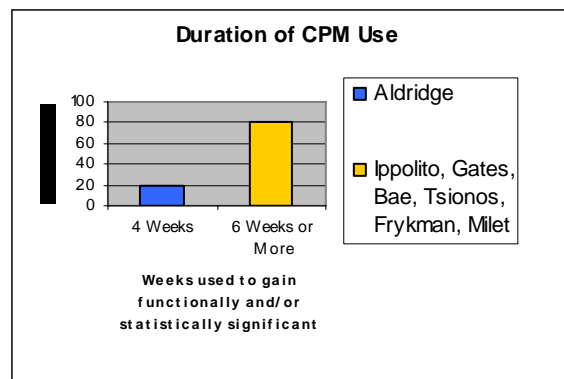


Figure 15
Clinical studies that reported duration of use following a surgical release procedure and that reached statistically significant gains in ROM or other outcome measures.

Surgical Release, Manipulation Under Anesthesia, Contracture/Stiffness^{4,8,10,12,13,35,41,52,60,85,99,100,126,135,143}

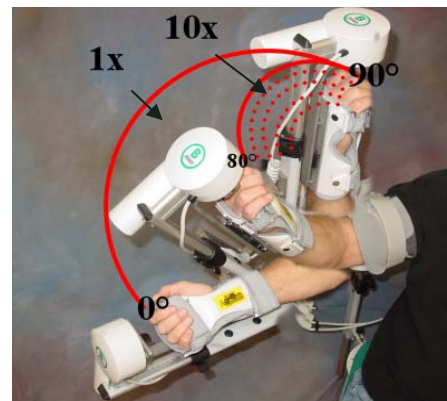
SET-UP GUIDELINE

- The patient is fitted and instructed on use of the Kinex Elbow CPM Device (preoperatively if possible to improve compliance).^{60,128}
 - ⇒ **Repeatable Anatomical Position:** Kinex Head Positioner is aligned to the patient to ensure correct positioning each time the CPM device is used.
 - ⇒ **Anatomical Elbow Alignment:** Kinex Multi-plane Adjustable Arm helps ensure the CPM device is aligned with the elbow and forearm throughout the arc-of-motion.
 - ⇒ **Postsurgical Grade Computer Sensor:** Kinex extra-sensitive sensor will reverse direction of movement if too much strain is detected; set between levels 20 (light) & 25 (heavy) depending on extremity size.
- CPM use is initiated 24-48 hours postoperatively, if possible.^{5,13,35,60,85,143}
- The elbow CPM is positioned with the shoulder at 90° of scapular elevation and with the humerus and wrist stabilized. The shoulder can be positioned at less than 90° if the patient has discomfort or an additional injury.
- **Synchronized Kinex CPM:** extension/flexion arc of motion is synchronized with forearm pronation/supination are in a pre-set ratio.
- **Isolated Kinex CPM:** The KE2 is set up in the ISO mode which offers three reps of flexion-extension followed by one rep of pronation-supination (3:1 ratio). The surgeon or therapist determines what position the hand is in during the flexion-extension arc and what position the elbow is in during the pronation-supination arc.

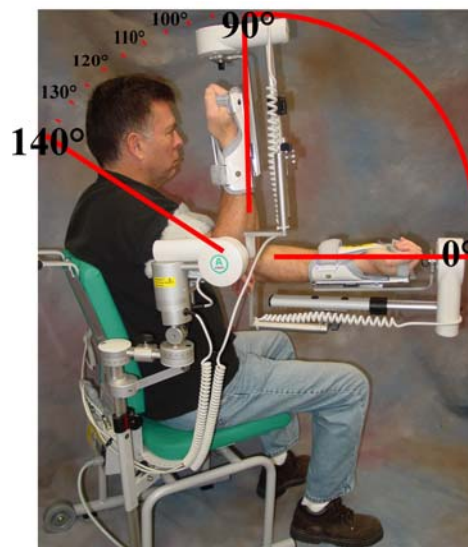
WEARING SCHEDULE GUIDELINE

- The Kinex CPM Device is used for 6-8 weeks or as needed.^{8,34,41,60,135}
- Week one, CPM is used 6-20 hours per day or as needed.⁵⁸

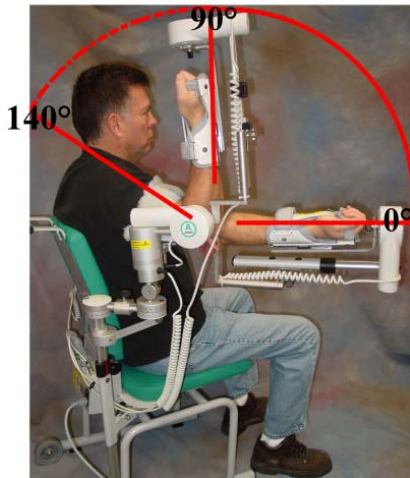
- Week two and beyond, the CPM is used for 4-8 hours per day in 3-4 sessions or as directed.^{60,128}
- **Kinex End-Range-Repeat Mode:** Three hour daily use schedules or severe contractures are usually performed in the Kinex End-Range-Repeat Mode; last 10° of the ROM arc is repeated 10 times followed by one complete ROM arc (10:1 ratio) in order to maximize functional use or need.



- **Kinex Static-Progressive-Stretch Mode:** This mode is used to gain motion in a contracted joint, usually not postoperatively. The Kinex CPM device is placed at end-range with the pause mode set at five minutes. After five minutes the CPM device is increased to the new end-range. This continues 1-2X a day for 30-60 minutes, week one. Week two the duration is increased to 2-3X a day. Week three and beyond the sessions are 60-90 minutes 3 times a day.



- **Kinex Dynamic-Stretch Mode:** This mode is used to gain motion in a contracted joint, usually not postoperatively. The Kinex CPM device is set at end-range. The force reversal is set between levels 15 (low) and 25 (high) depending on the extremity size or stiffness. The device will move through one full cycle followed by 10 stretch cycles (1:10 ratio). In the stretch cycle the Kinex device will attempt to move the joint 5° beyond end-range. The device will automatically reverse if a force that is stronger than the setting force is met. Duration is 1-2 times for 30-60 minutes a day, week one. Week two the device is used 30-60 minutes a day for 2-3 times. Week three and beyond the device is used 60-90 minutes a day 3 times a day.



PROM GOALS

- The patient increases ROM as tolerated to meet ROM goals.^{53,60,128}
- CPM use should continue if PROM goals have not been met.⁶⁰
- Kinex CPM device can be set at dynamic-progressive-stretch or static-progressive-stretch mode if patient is not progressing as expected.
- Full joint motion may be less during the first 2-3 weeks postoperatively due to swelling.⁶⁰
- Elbow extension/flexion and pronation/supination end range goal is 85% or better of the operative range.⁶⁰

Note: This device must be used under the advice and care of a physician.

Peer-Reviewed Studies Evaluating Outcome Measures for the Efficacy of Elbow CPM Following Surgical Release, and Stable Fracture

<i>Clinical Study</i>	<i>Purpose of Study</i>	<i>Duration of Use</i>
Anterior Release of the Elbow for Extension Loss: Aldridge et al (2004, J Bone Jt Surg)	Compared the efficacy of CPM to splinting only following the surgical release of 106 elbow joints.	CPM was used 4 weeks or longer depending on the severity of the contracture.
Resection of Elbow Ossification and Continuous Passive Motion in Post-comatose Patients: Ippolito et al (1999, J Hand Surg)	Heterotopic periarticular ossifications were surgically excised in 16 elbow joints of traumatic brain injury patients.	The CPM was used for 6 weeks before starting a fully active rehabilitation program.
Anterior Capsulotomy and Continuous Passive Motion in the Treatment of Post-traumatic Flexion Contracture of the Elbow; A Prospective Study: Gates et al (1992, J Bone Jt Surg)	Thirty-three patients who had a post-traumatic flexion contracture of the elbow underwent an anterior capsulotomy. Fifteen patients did not receive CPM & eighteen patients did receive CPM post-operatively.	CPM was used for a mean of 6 weeks.
Grading of Functional Results of Elbow Joint Arthrolysis after Fracture Treatment: Olivier et al (2000, Arch Orthop Trauma Surg)	Ninety-one patients were treated with arthrolysis for a post-traumatic contracture followed by the use of CPM.	Not Reported
Post-traumatic Contracture of the Elbow Treated with Intra-articular Techniques: Wu (2003, Arch Ortho Trauma Surg)	Twenty consecutive adult patients underwent an anteroposterior capsule release. Immediately post-operatively, CPM was initiated.	Not Reported
Surgical Treatment of Post-traumatic Elbow Contracture in Adolescents: Bae & Waters (2001, J Ped Ortho)	Thirteen adolescents with post-traumatic elbow contractures were treated with open surgical release followed by CPM.	CPM was used for 6 weeks post-operatively.
Arthroscopic Treatment of Arthrofibrosis of the Elbow Joint: Phillips & Strasburger (1998, J Arthro Rel Surg)	Twenty-five patients with arthrofibrosis were treated with arthroscopic debridement and CPM post-operatively.	Not Reported
Arthrolysis of Post-traumatic Stiff Elbow; Which Factors Influence the End Result: Breitfus et al (1991, Unfallchirurg)	A retrospective study of 59 patients who received an arthrolysis for post-traumatic stiffness. CPM was compared to splinting and physical therapy. CPM start times were also evaluated.	Not Reported
Factors Influencing Elbow Arthrolysis: Schindler et al(1991, Ann Chir Maine Super)	Retrospective study between 1982 & 1988 which evaluated the use of CPM following an arthrolysis procedure.	Not Reported
Heterotopic Ossification of the Elbow in Patients with Burns; Results after early Excision: Tsionos et al (2004, J Bone Jt Surg Br)	Between 1992 & 2001, 35 elbows underwent a surgical release due to heterotopic ossification. CPM began on the second post-operative day.	CPM was used for 5-8 weeks.
Elbow Flexion Contractures: Treatment by Anterior Release and Continuous Passive Motion: Breen et al (1987, J Hand Surg)	Patients with post-traumatic flexion contractures who did not respond to non-operative physical therapy, dynamic splinting or bracing were treated by anterior surgical release and post-operative CPM.	CPM was started in the hospital and continued in the patients home.
Debridement Arthroplasty for Osteoarthritis of the Elbow: 50 patients followed a Mean of 5 Years: Oka (2000, Acta Orthop Scand)	There were 26 athletes and 24 laborers who underwent debridement arthroplasty for contractures due to osteoarthritis.	CPM was initiated at 5 days post-operatively.
The Lateral Approach for Operative Release of Posttraumatic Contracture of the Elbow: Husband et al (1990, JBJS)	A lateral release was used in this series of patients with a post-traumatic elbow contracture followed by the use of CPM post-operatively.	CPM was initiated immediately post-operatively.
Arthrolysis of the Elbow in Post-traumatic Contracture: Blauth et al (1990, Orthopade)	In a retrospective study, 125 out of 168 patients were reviewed following an arthrolysis and application of CPM for post-traumatic stiffness.	Not Reported
The Bryan-Morrey Triceps-Sparing Approach to Open Reduction of T-Condylar Humeral Fractures in Adolescents: Cybex Evaluation of Triceps Function and Elbow Motion: Remia et al (2004, J Ped Ortho)	A series of patients underwent open reduction of a T-condylar distal humerus fracture followed by early use of CPM.	Not Reported
T-Condylar Fractures of the Distal Humerus in Children and Adolescents: Re et al (1999, J Ped Orthop)	This was a retrospective review of 17 T-condylar fractures in children and adolescents. It examined the results by sex, age, arm injured, hand dominance, mechanism of injury, operative procedure, CPM use, and outcome.	Not Reported
Intraarticular Fractures of the Distal Humerus, Surgical Treatment and Results: Letsch et al (1989, Clin Ortho Rel Res)	This preliminary study evaluated 104 patients who underwent a surgical repair of the distal humerus over a 12 year period. CPM was used immediately in the hospital and part of the home program. Outcome measures included ROM, pain, and working capacity.	Not Reported
Continuous Passive Motion after Internal Fixation of the Distal Humerus: Soffer et al (1990, Ortho Rev)	This small series preliminary study evaluated the use of CPM following stabilization of distal humerus fractures.	Not Reported
Tuberculous Arthritis of the Elbow: Chen et al (1998, International Orthopaedics)	Twenty-three patients with tuberculous arthritis of the elbow were treated including the use of CPM post-operatively and followed for 3 to 8 years	Not Reported
Progressive Surgical Release of a Post-traumatic Stiff Elbow, Techniques and outcome after 2-18 years in 46 patients: Marti et al (2002, Acta Orthop Scand)	This study evaluated surgical techniques and post-operative rehabilitation on 46 patients suffering from post-traumatic contracture of the elbow joint. Rehabilitation outcomes were evaluated at a mean of 10 years.	CPM was utilized immediately post-operatively.

Results	Primary Finding
The total arc of motion increased 45° in the CPM group & only 26° in the splinting only group. This difference is statistically significant, p=0.27.	CPM following a surgical release offers a statistically superior (p=0.27) functional outcome over splinting alone & physical therapy.
ROM improvements were greater than five previous investigators with a similar series of patients without CPM.	CPM is more effective in reaching functional range of motion after 6 weeks than physical therapy alone following a surgical release.
The mean post-operative arc of motion improved 25° in the physical therapy group and 47° in the CPM group. The difference was statistically significant.	CPM following the release of a flexion contracture resulted in a statistically significant improvement in function compared to the non-CPM group.
The mean ROM improved from 49° to 94° in flexion and 89° to 129° in pronation/supination. The results were statistically significant at p<0.05.	The importance of an intensive early CPM program is emphasized as the results were statistically significant.
The flexion contracture improved from a mean of 42° to 13°, flexion improved from 89° to 131° & the total arc improved from 47° to 118°. All improvements were statistically significant at p<0.001.	A statistically significant improvement (p<0.001) in functional ROM was seen due to the use of CPM post-release.
Average loss of extension improved from 57° to 15°, average flexion improved from 109° to 123° & total arc improved from 53° to 107°.	Open surgical release followed by the use of CPM for 6 weeks resulted in a significant improvement in functional ROM (>100°) in adolescents.
At an average follow up of eighteen months all patients had a statistically significant (p=0.001) increase in ROM and decreased pain.	Arthroscopic release followed by CPM obtained statistically significant results.
Patients who started on CPM day one lost 15% of intraoperative function while those delayed to day five lost 30%. The combined PT and CPM group lost 17% compared to the splinting group which lost 35%. The CPM gains were statistically significant.	Statistically superior results were obtained with CPM compared to a splinting program. CPM started within 48 hours did better than CPM started day five. Even delayed CPM use was superior to non-CPM protocols.
All of the improvements were statistically significant, p<0.0001. 88.2% of CPM users improved beyond 10° vs. only 28.6% for non-CPM users, while 64.7% of patients in the CPM group reached normal extension only 14.3%	The only variable of value was the use of CPM following surgery. The CPM mean improvement (32.6°) was statistically superior than the non-CPM group (12.8°), p<0.01.
The gains were statistically significant from a mean of 22° to 123° in flexion/extension & 94° to 160° in pronation/supination.	A 100° arc is considered to be functional. The authors conclude that CPM is needed following a release to reach functional ROM.
There were no complications and the patients tolerated CPM well. The mean flexion contracture was 41° and the mean improvement was 36°, leaving a mean flexion contracture of 5°.	The authors compared their series to a similar series by Urbaniak (1985, JBJS) who did not use CPM post-operatively (splinting only) that resulted in an average of a 19° contracture. The authors state that their improved outcomes are due to the post-operative use of CPM.
The patients were evaluated after 5 years and exhibited a mean improvement of 24°. There was no difference in improvement between athletes and laborers.	The authors conclude that debridement arthroplasty followed by CPM is an effective treatment in athletes and laborers with osteoarthritis of the elbow.
The patients were evaluated an average of 38 months post-operatively. The mean arc of motion improved 46°.	A lateral release is an effective surgical option following an elbow contracture when CPM is used post-operatively.
In 77% of patients, the results were very good, good or satisfactory. Overall, the mean increase was 49° or a 58% improvement.	Arthrolysis followed by CPM demonstrated significant improvements in 125 patients who were reviewed by the author.
The average follow up was 3 years and 5 months. The average range of motion was -8° to 136°. These results were statistically significant.	In this series, early post-operative CPM was found to significantly increase range of motion.
Improvements contributed to the use of CPM were statistically significant at p<0.05.	"The use of CPM in the immediate post-operative period resulted in a functional range of motion sooner and yielded a statistically significant increase in flexion at follow up exam compared to the group without CPM" (p<0.05).
The long term outcomes (81%) were rated as very good or good due to the surgical treatment and the post-operative use of CPM.	The use of CPM post-operatively contributed to a 30% reduction in hospitalization time because home therapy was improved. The authors also report that the use of CPM decreased the incidence of myositis ossificans.
All patients recovered full pronation/supination and functional ROM in flexion/extension.	The authors concluded in this early study that CPM was a valuable therapeutic modality in the post-operative management of intra-articular fractures of the elbow.
Early diagnosis and surgical treatment resulted in good functional outcomes when CPM is included in post-operative care.	"Post-operative CPM is valuable in improving range of movement in elbows with extensive osteoarticular tuberculosis."
Mean post-operative flexion was 114° and the mean extension lag was 5°. Pronation/Supination improved from a mean of 8° to a mean of 98°.	The results of our rehabilitation program support the findings of Gates et al (1992) that post-operative use of CPM improves total range of motion and therefore function.

REFERENCES AND BIBLIOGRAPHY

1. Adams KM, Thompson ST: Continuous Passive Motion Use in Hand Therapy. *Hand Clinics* 12(1): 109-121, February 1996.
2. Akeson WH, et al: Collagen cross linking alterations in joint contractures: changes in the reducible cross links in periarticular connective tissue collagen after nine weeks of immobilization. *Connect Tissue Res* 5:15, 1977.
3. Akeson W, Amiel D, Woo S: Immobility effects on synovial joints. The pathomechanics of joint contracture. *Biorheology* 17: 95-110, 1980.
4. Aldridge JM, Atkins TA, Gunnerson EE, Urbaniak JR: Anterior Release of the Elbow for Extension Loss. *J Bone Joint Surg* 86: 1955-1960, 2004.
5. Amiel D, Akeson WH, Harwood FL, et al: Stress deprivation effect of metabolic turnover of the medial collateral ligament collagen; A comparison between nine-and twelve-week immobilization. *Clin Orthop* 172: 265-270, 1983.
6. Anderson NH, Sojbjerg JO, Johannsen HV, Sneppen O: Frozen Shoulder: arthroscopy and manipulation under general anesthesia and early passive motion. *J Shoulder Elbow Surg* 7(3): 218-222, May-June 1998.
7. Aschoff H: Combined passive and intermittent active motion treatment after flexor tendon suture. *Handchir Mikrochir Plast Chir* 27(4):189-94, Jul 1995.
8. Bae, DS: Surgical Treatment of Posttraumatic Elbow Contracture in Adolescents. *Journal of Pediatric Orthopedics* 21(5): 580-584, 2001.
9. Ballantyne BT, O'Hare SJ, Paschall JL, Pavia-Smith MM, Pitz AM, Gillon JF, Soderberg GL. Electromyographic activity of selected shoulder muscles in commonly used therapeutic exercises. *Phys Ther* 73(10):668-77; discussion 677-82, Oct 1993.
10. Bennet WF: Addressing glenohumeral stiffness while treating the painful and stiff shoulder arthroscopically. *The Journal of Arthroscopic and Related Surgery* 16(2), March, 2000.
11. Boehm TD, Matzer M, Brazda D, Gohlke FE: Os acromiale associated with tear of the rotator cuff treated operatively, Review of 33 patients. *J Bone Joint Surg Br* 85-B (4):545-49, 2003.
12. Bradley, J.P.: Arthroscopic Treatment for Adhesive Capsulitis. *Operative Techniques in Orthopedics* 1(3):248-252. July 1991.
13. Breiffuss H, et al: Arthrolysis of posttraumatic stiff Elbow : which factors influence the end result. *Unfallchirurg* 94:33, 1991.
14. Bunker TD, Potter B, Barton NJ: Continuous passive motion following flexor tendon repair. *J Hand Surg* 14B:406, 1989.
15. Cohen EJ: Adjunctive Therapy Devices: Restoring ROM Outside of the Clinic. *Physical Therapy Products* 10-13, 1995.
16. Coutts RD, Borden LS, Byran RS, Hungerford DS: The effect of continuous passive motion on total knee rehabilitation. *Orthop Trans* 6:277, 1982.
17. Coutts RD, Craig EV, Mooney V, Osterman AL, Salter RB: Symposium: The Use of Continuous Passive Motion in the Rehabilitation of Orthopedic Problems. *Contemp Ortho* 16(3): 75-101, 1988.
18. Coutts RD, Stenstrom A: Effect of Continuous Passive Motion on the Rehabilitation of Patients After Intertrochanteric Fractures, 1985.
19. Craig EV: Continuous passive motion in the rehabilitation of the surgically reconstructed shoulder. A preliminary report. *Orthop Trans*. 10: 219, 1986.
20. Chow J, Schenck RB: Early Continuous Movement in Hand Surgery. *Curr Surg*: 97-100. Mar-Apr 1989.
21. Daane M: [Evaluation of CPM insurance coverage]. Unpublished raw data. 2002.
22. Daane M: [Evaluation of Shoulder CPM Usage, 160 surgeons]. Unpublished raw data. 2004.
23. Daane M: [Kinex Medical Company report on shoulder CPM diagnosis]. Unpublished raw data. 2002.
24. Davidson PA, Rivenburgh DW: Rotator cuff repair tension as a determinant of functional outcome. *J Shoulder Elbow Surg* 9:502-506, 2000.
25. Dent JA: Continuous passive range of motion in hand rehabilitation. *Prost Orthot Int* 17(2): 130-5, August, 1993.
26. Djurasovic M, Aldridge JW, Grumbles R, Rosenwasser MP, Howell D, Ratcliffe A: Knee joint immobilization decreases aggrecan gene expression in the meniscus. *AJSM* 26(3):460-66, 1998.
27. Dockery ML, Wright TW, Lastayo PC: Electromyography of the shoulder: An analysis of passive modes of exercise. *Orthopedics* 21:11, 1998.
28. Duran RJ, et al: Management of flexor tendon lacerations in Zone 2 using controlled passive motion postoperatively. In Hunter JM, et al, editors. *Rehabilitation of the Hand*, ed 3, St. Louis, Mosby, 1990.
29. El-Zahaar MS, Bebars M: The Value Of The Continuous Passive Motion After Repair Of The Rotator Cuff Tear In Athletes (An Arthroscopic Study). *J Neurol Orthop Med Surg* 16:246-252, 1996.
30. Evans RB, Thompson DE: Application of force to the healing tendon. *J Hand Ther* 6:262, 1993.
31. Evans EB, Eggers GWN, Butler JD, Blumel J: Experimental immobilization and remobilization of rat knee joints. *J Bone Joint Surg* 42A: 737, 1960.
32. Fareed DO, Gallivan WR: Office Management of Frozen Shoulder Syndrome. Treatment with Hydraulic Distention Under Local Anesthesia. *Clin Orth Rel Res* 242:177-183, May 1989.
33. Ferretti M, Srinivasan A, Deschner J, Gassner R, Baliko F, Piesco N, Salter R, Agarwal S: Anti-inflammatory effects of continuous passive motion on meniscal fibrocartilage. *J Orthop Res*. 23(5):1165-71, 2005.
34. Frank C, Akeson WH, Woo SL-Y, Amiel D, et al: Physiology and Therapeutic Value of Passive Joint Motion. *Clin Orth Rel Res* 185:113-125, May 1984.
35. Frykman GK, et al: CPM improves range of motion after PIP and MP capsulectomies: a controlled prospective study. Abstract 72. Proceedings of the 44th annual meeting of the American Society for Surgery of the Hand, Seattle, September 1989.
36. Gacon G, Deider C, Rhenier J-L, Minaire P: Possibilities du traitement chirurgical des para-osteoarthropathies neurogenes: etude critique de 70 cas operes. *Rev Chir Orthop* 64:375-90, 1978.
37. Garland DE, Hanscom DA, Keenan MA, Smith C, Moore T: Resection of heterotopic ossification in the adult with head trauma. *J Bone Joint Surg* 67A: 1261-69, 1985.
38. Gartner J, Hassenpflug J: Continuous Passive Motion Devices for the Shoulder Joint – Clinical Experiences. *J Bone Joint Surg Br* Abstract 74-B: Supp 1, 1992.

39. Gartsman GM, O'Connor DP: Arthroscopic rotator cuff repair with and without arthroscopic subacromial decompression: A prospective, randomized study of one-year outcome. *J Shoulder Elbow Surg* 13: 424-6, 2004.
40. Gassner R, Buckley MJ, Georgescu H, Studer R, Stefanovich-Racic M, Piesco NP, Evans CH, and Agarwal S: Cyclic tensile stress exerts anti-inflammatory actions on chondrocytes by inhibiting inducible oxide synthase. *J Immunology* 163:2187-2192, 1999.
41. Gates HS, Sullivan FL, Urbaniak JR: Anterior capsulotomy and continuous passive motion in the treatment of posttraumatic flexion contracture of the elbow: a prospective study. *J Bone Joint Surg* 74:1229, 1992.
42. Gelberman RH, Dimick MP: The biotechnology of hand and wrist implant surgery and rehabilitation. *J Rheumatol* 15:53, 1987.
43. Gelberman RH, et al: Influences of the protected passive motion interval on flexor tendon healing: a prospective randomized clinical study. *Clin Orthop Rel Res* 264:189, 1991.
44. Gelberman RH, Nunley II JA, Osterman LA, Woo S L-Y: Abstract, American society for the surgery of the hand, 44th annual meeting; Influences of the protective passive mobilization interval on flexor tendon healing.
45. Giudice ML: Effects of continuous passive motion and elevation on hand edema. *Am J Occup Ther* 44:914, 1990.
46. Gristina AG, Craig EV, Nevaizer RJ, et al: Symposium: Management of Rotator Cuff Problems. *Contempt Orth* 20(6): 621-646, June 1990.
47. Harwood FL, Amiel D: Differential metabolic responses of periarticular ligaments and tendon to joint mobilization. *J Appl Physiol* 72:1687-1691, 1992.
48. Hatakeyama Y, Itoi E, Pradhan RL, Urayama M, Sato K: Effect Of Arm Elevation And Rotation On The Strain In The Repaired Rotator Cuff Tendon: A Cadaveric Study. *Am J Sport Med*, Nov-Dec 2001.
49. Hersche O, Gerber C: Passive tension in the supraspinatus musculotendinous unit after long-standing rupture of its tendon: A preliminary report. *J Shoulder Elbow Surg* 7: 393-396, 1998.
50. Ide J, Maeda S, Takagi K: Arthroscopic transtendon repair of partial-thickness articular-side tears of the rotator cuff, anatomical and clinical study. *AJSM* 33(11): 1-8, 2005.
51. Ide J, Takag K: Arthroscopic Bankart Repair using suture anchors in athletes: Patient selection and postoperative sports activity. 32(8):1899-1905,2004.
52. Ippolito E, Formisano R, Caterini R: Resection of elbow ossification and continuous passive motion in postcomatose patients. *J Hand Surg* 24A(3): 546, May 1999.
53. Jansen D: Shoulder CPM guideline for Patrick M. Connor, MD. A personal communication. October 2004
54. Kaczander B: The podiatric application of continuous passive motion, a preliminary report. *J Am Pod Med Assoc* 81: 12, 1991.
55. Kelly BT, Williams RJ, Cordasco FA, Backus SI, Otis JC, Weiland DE, Altchek DW, Craig EV, Wickiewicz TL, Warren RF: Differential patterns of muscle activation in patients with symptomatic and asymptomatic rotator cuff tears. *Journal of Shoulder and Elbow Surgery*. 14(2):165-171, March-April 2005.
56. Kim HK, Kerr RG, Cruz TF, Salter RB: Effects of continuous passive motion and immobilization on synovitis and cartilage degradation in antigen induced arthritis. *J Rheumatol* 22(9): 1714-21, 1995.
57. Klein L, Heiple KG, Torzilli PA, et al: Prevention of ligament and meniscus atrophy by active joint motion in the non-weight bearing model. *J Orthop Res* 7:80-85, 1989.
58. Klein L, Player JS, Heiple KG, et al: Isotopic evidence for resorption of soft tissues and bone in immobilized dogs. *J Bone Joint Surg* 64A: 225-230, 1982.
59. Kroeder HJ, Moran F, Keeley W, Salter RB: Biologic resurfacing of a major joint defect with cryopreserved allogeneic periosteum under the influence of continuous passive motion in a rabbit model. *Clin Orthop Relat Res* 300:288, 1994.
60. LaStayo PC, Cass R: Continuous passive motion for the extremity: why, when, and how. In Hunter JM, et al, editors: *Rehabilitation of the Hand*, ed 5 ST Louis, Mosby, 2002.
61. LaStayo PC, Jaffe R: Assessment and management of shoulder stiffness: a biomechanical approach. *J Hand Ther* 7:122, April-June 1994.
62. LaStayo PC, Wright TW, Jaffe R, Hertzler J: Continuous passive motion after repair of the rotator cuff: A prospective study. *The Journal of Bone and Joint Surgery* 80: 1002, 1998.
63. Lee MS, Ikenoue T, Trindale M, Wong N, Goodman SB, Schurman DJ, Smith L: Protective effects of intermittent hydrostatic pressure on osteoarthritic chondrocytes activated by bacterial endotoxin in vitro. *J Ortho Res* 21(1): 117-122, 2003.
64. Lindsay WK: Cellular biology of flexor tendon healing. In Hunter JM, Schneider JH, Mackin EJ, editors: *Tendon Surgery in the Hand*. St. Louis, Mosby, 1987.
65. Linter D, McNeal M: Rotator Cuff repair (protocol). [online]. Available: www.drilinter.com/rotatorcuff.htm; January 2004.
66. Loitz BJ, Zernicke RF, Vailas AC, et al: Effects of short-term immobilization versus continuous passive motion on the biomechanical and biochemical properties of the rabbit tendon. *Clin Orthop* 244:265-271, 1989.
67. Lowe W: Rotator Cuff Repair Protocol. [online]. Available: www.drwallowe.com/rotcuffpro.html January 2004.
68. Manske PR: Flexor tendon healing. *J Hand Surg* 13B:237, 1988.
69. Matsen FA: Shoulder Replacement Surgery for Arthritis. [online]. Available: www.orthop.washington.edu/faculty/Matsen/shoulrep/06; February 24, 2003.
70. McAuliffe JA, Wolfson AH: Early excision of heterotopic ossification about the elbow followed by radiation therapy. *J Bone Joint Surg* 79A:749-55, 1997.
71. McCann PD, Wootten ME, Kadaba MP, Bigliani MD. A kinematic and electromyographic study of shoulder rehabilitation exercises. *Clinical Orthopedics and Related Research* 288: 177-188, March 1993.
72. McCarthy M, Yates C, et al: The Effects of Immediate Continuous Passive Motion on Pain During the Inflammatory Phase of Soft Tissue Healing Following Anterior Cruciate Ligament Reconstruction. *JOSPT* 17(2):94, February 1993.
73. McCarthy M: The Use of CPM Following Arthroscopically Assisted Reconstruction of the ACL using a Patella Tendon Bone Autograft, Physical Therapy Forum, May 7, 1990.
74. McCarthy MR, Hirsch HS, et al: Effects of CPM following ACL reconstruction with autogenous patellar tendon grafts. *J. Sports Rehab* 1, 1992.
75. McCarthy MR, O'Donoghue PC, Yates CK, Yates-McCarthy, JUL: The Clinical Use of Continuous Passive Motion in Physical Therapy. *JOSPT* 15(3), March 1992.
76. McGovern B: CPM helps patients regain motion before strength. *Orthopedic Technology Review* 1(2), June/July 1999.
77. McInnes J, Larson MG, Daltry LH, et al: A controlled evaluation of CPM patients undergoing total knee arthroplasty. *JAMA* 268:11, 1992.
78. Melzack R, Wall PD: Pain Mechanisms: A New Theory. A gate control system modulates sensory input from the skin before it evokes pain perception and response.

Science 150(3699):971-979, Nov.1965.

79. Milroy P: Factors Affecting Compliance to Chiropractic Prescribed Home Exercise: A Review of the Literature. *Journal of the American Chiropractic Association* Jan 2003.
80. Missamore GW, Siegler D, Higginbotham G. Passive range of motion exercises of the shoulder: an EMG analysis. *J Shoulder Elbow Surg* 2:527, 1993.
81. Moore TJ: Functional outcome following surgical excision heterotopic ossification in patients with traumatic brain injury. *J OrthopTrauma* 7:11-14, 1993.
82. Moran ME, Kim HK, Salter RB. Biologic resurfacing of full-thickness defects in patellar articular cartilage of the rabbit. *J Bone Joint Surg* 74:659, 1992.
83. Neer CS, McCann PD, MacFarlane EA, Padilla W: Earlier passive motion following shoulder arthroplasty and rotator cuff repair: A prospective study. *Orthop. Trans* 11:231, 1987.
84. Newton PO, Woo SL-Y, Mackenna DA, et al: Immobilization of the knee joint alters the mechanical and ultrastructural properties of the rabbit anterior cruciate ligament. *J Orthop Res* 13:191-200, 1995.
85. Nicholson GP: Arthroscopic Capsular release for stiff shoulders effect of etiology on outcomes. *The Journal of Arthroscopy and Related Surgery* 19(1): January 2003.
86. Noyes F, et al: The Early Treatment of Motion Complications After Reconstruction of the Anterior Cruciate Ligament. *Clinical Orthopaedics and Related Research* 277, April 1992.
87. Noyes F, et al: The Early Treatment of Motion Complications After Reconstruction of the Anterior Cruciate Ligament. *Clinical Orthopaedics and Related Research* 277 April 1992.
88. Noyes FR, et al: Biomechanical Analysis of Human Ligament Grafts Used in Knee-Ligament Repairs and Reconstructions. *JBJS* 66-A(3), March 1984.
89. Noyes FR, Mangine RE, Barber S: Early knee motion after open and arthroscopic anterior cruciate ligament reconstruction. *Am J Sports Med* 15:149, 1987.
90. Noyes FR, MD, Paulos LE, et al: Intra-articular Cruciate Reconstruction. *Clinical Orthopaedics and Related Research* 172, Jan/Feb 1983.
91. Noyes FR: Functional properties of knee ligaments and alterations induced by immobilization: A correlative biomechanical and histological study in primates. *Clin Orthop* 123:210, 1977.
92. O'Brien JJ, Schwartz RE, Warren RF, Torzill PA: Capsular restraints to anterior/posterior motion of the shoulder. *Orthop Trans* 12:143, 1998.
93. O'Driscoll SW, Giori NJ: Continuous passive motion (CPM): Theory and principles of clinical application. *J Rehab Res Dev* 37: 179, 2000.
94. O'Driscoll SW, Keeley FW, Salter RB: Durability of regenerated articular cartilage produced by free autogenous periosteal grafts in major full-thickness defects in joint surface, under influence of continuous passive motion. *J Bone and Joint Surg* 70(A):595-606, 1988.
95. O'Driscoll SW, Kumar A, Salter RB: The effect of continuous passive motion on the clearance of hemarthrosis from a synovial joint: an experiment investigation in the rabbit. *Clin Orthop* 176:305, 1983.
96. O'Driscoll SW, et al: The Chondrogenic Potential of Free Autogenous Periosteal Grafts for Biological Resurfacing of Major Full-Thickness Defects in Joint Surfaces Under the Influence of Continuous Passive Motion. *JBJS* 68-A(7), September 1986.
97. O'Driscoll SW, et al: The Repair of Major Osteochondral Defects in Joint Surfaces by Neochondrogenesis with Autogenous Osteoperiosteal Grafts Stimulated by CPM. *Clinical Orthopaedics and Related Research* 208, July 1986.
98. O'Driscoll SW, Salter RB: The Indication of Neochondrogenesis in Free Intra-Articular Periosteal Autografts Under the Influence of Continuous Passive Motion. *JBJS* 66-A (8), October 1984.
99. Olivier LC, Assenmacher S, Setareh E, Schmit-Neveburg KP: Grading of Functional Results of Elbow Joint Arthrolysis after Fracture Treatment. *Arch Orthop Trauma Surg* 120:562-569, 2000.
100. Phillips B, Strasburger S: Arthroscopic Treatment of Arthrofibrosis of the Elbow Joint. *The Journal of Arthroscopic and Related Surgery* 14(1) Jan-Feb, 1998.
101. Potenza AD: Tendon healing within the flexor digital sheath in the dog. *J Bone Joint Surg* 44:49, 1962.
102. Raab MG, Rzeszutko D, O'Connor W: Early results of continuous passive motion after rotator cuff repair: A prospective, randomized, blinded, controlled study. *Am J Orthop* 25:214, 1996.
103. Roberts JB, Pankratz DG: The surgical treatment of heterotopic ossification at the elbow following long term coma. *J Bone Joint Surg* 61A:760-63, 1979.
104. Rockwood CA, Matsen FA: *The Shoulder*, Philadelphia, WB Saunders, 1990.
105. Rosen H: The treatment of nonunions and pseudoarthroses of the humeral shaft. *Ortho Clin North Am* 21:725, 1990.
106. Rosen MA, Jackson DW, Atwell EA: The Efficacy of Continuous Passive Motion in the Rehabilitation of Anterior Cruciate Ligament Reconstructions. *The American Journal of Sports Medicine* 20(2): 122-127, 1992.
107. Royer C, Kolowich P, Jasper C, Donahue M, Haustad MA: Evaluation and Cost Analysis in use of Continuous Passive Motion After Repair of Rotator Cuff Tears. Unpublished manuscript. Institutional Review Board at Henry Ford Hospital, 2000.
108. Salter RB, Bell RS: The effect of continuous passive motion in the healing of partial thickness lacerations of the patellar tendon of the rabbit. *Ann Royal Coll Phys Surg Can* 14:209, 1981.
109. Salter RB, Bell TS, Keeley F: The protective effect of continuous passive motion on living articular cartilage in acute septic arthritis, an experimental investigation in the rabbit. *Clin Orthop Rel Res* 159:223, 1981.
110. Salter RB, et al: Clinical applications of basic research on continuous passive motion for disorders and injuries of synovial joints: a preliminary report of a feasibility study, *Orthop Res* 1:325, 1984.
111. Salter RB, et al: Continuous Passive Motion and the Repair of Full-Thickness Articular Cartilage Defects – A One Year Follow-Up, 28th Annual ORS, New Orleans, LA, January 19-21, 1982.
112. Salter RB et al: The Biological Effect of Continuous Passive Motion on the Healing of Full-Thickness Defects in Articular Cartilage. *JBJS* 62-A(8), December 1980.
113. Salter RB, Ogilvie-Harris DJ: Healing of Intra-articular Fractures with Continuous Passive Motion, AAOS Instructional Course Lectures, 1985.
114. Salter RB, Wong DA, Keely FW: Collagen typing of early repair tissue in healing articular cartilage: and experimental study in the rabbit. *Orthop Trans* 4:397, 1980.
115. Salter RB: The biologic concepts of continuous passive motion of synovial joints. *Clin Orthop* 242: 12-25, 1998.
116. Salter RB, Harris DJ, Bogoch F: Further studies in continuous passive motion. *Orthop Trans* 212 (abstract), 1978.

117. Salter RB, O'Driscoll SW: The effects of continuous passive motion on repair of full thickness defects in a joint surface with autogenous osteoperiosteal grafts. *Ann Royal Coll Phys Surg Can* 16:360 (abstract), 1983.
118. Salter RB, Minster RR: The effects of continuous passive motion on a semitendinous tenodesis in the rabbit knee. *Proc Orthop Res Soc* 7:225, 1982.
119. Salter RB: The healing of bone and cartilage in intraarticular fractures with continuous passive motion. *Transactions of the twenty-fourth annual meeting of the Orthopaedic Research Society* 3, February 1978.
120. Salter RB: Continuous passive motion: a biological concept for the healing and regeneration of articular cartilage, ligaments and tendons, Williams & Wilkins, Baltimore, 1993.
121. Salter RB: The effect of motion on regeneration of cartilage. Proceedings of the International Workshop on Rehabilitation of Articular Joints by Biological Resurfacing, Dallas. November 15-17, 1979.
122. Salter RB: The Physiologic basis of continuous passive motion for articular cartilage healing and regeneration. *Hand Clin* 10(2):221-9, 1994.
123. Salter RB: The prevention of arthritis through the preservation of cartilage, Royal College Lecture. *J Can Assoc Radiol* 32:5, 1981.
124. Savolainen J, Myllyla V, Myllyla R, et al: Effects of denervation and immobilization on collagen synthesis in rat skeletal muscle and tendon. *Am J Physiol* 254:R897-R902, 1988.
125. Schaefer RN, Schaefer LA, Satterlee C: Earlier Passive Range of Motion Following Rotator Cuff Repair. *Orthopedic Transactions* 16(2) abstract. Summer 1992.
126. Schindler A, et al: Factors influencing elbow arthrolysis. *Ann Chir Maine Memb Super* 10(3):237-42, 1991.
127. Shoo A, Morris M, Bui M: Influence of home exercise performance, concurrent physical activities and analgesics on pain in people with osteoarthritis. *J Physiotherapy* 32(2): 67-74, 2004.
128. Spaciel B: Shoulder CPM Guideline for Dean Ziegler, MD. A personal communication. January 2004.
129. Spaciel B. Shoulder CPM Guideline for William Pennington, MD. A personal communication. March 2005.
130. Steinberg
131. Stone K: Frozen Shoulder Release Post-Operative Protocol. [online]. Available at: www.stoneclinic.com/frozen_shoulder3.htm; January 2005.
132. Takai S, Woo SL-Y, Horibe S, Tung DK-L, Gelberman RH: The Effects of Frequency and Duration of Controlled Passive Mobilization on Tendon Healing. *J Orthop Res* 9(5): 705-713, 1991.
133. Tibone JE, Elrod B, Jobe FW, Kerlan RK, Carter VS, Shields CL Jr, Lombardo SJ, Yocum L: Surgical Treatment Of Tears Of The Rotator Cuff In Athletes. *J Bone Joint Surg Am* 68 (6):887-91, 1986.
134. Ticker JB: Shoulder Rehabilitation. *AAOS, The Shoulder: Advances in Open and Arthroscopic Techniques*. Orthopaedic Learning Center, Rosemont, IL, October 27-29, 2000.
135. Tsionos I, Leclercq C, Rochet JM: Heterotopic ossification of the elbow in patients with burns: Results after early excision. *J Bone Joint Surg Br* 86-B:396-403, 2004.
136. Turner B, Guido IA: Rehabilitation after ligamentous and labral surgery of the shoulder: guiding concepts. *Journal of Athletic Training* 35(3): 373-381, 2000.
137. Van Strien G: Postoperative management of flexor tendon injuries. In Hunter JM, et al, editors: *Rehabilitation of the hand*, ed 3 St Louis, Mosby, 1990.
138. Worland RL, et al: Home continuous passive motion machine versus professional physical therapy following total knee replacement. *Journal of Arthroplasty* 13:7, 1998.
139. Woo SL-Y, Akeson WH: Structural and mechanical behavior of tendons and ligaments. *Proc Int Symp Biomaterials*. Teipei, Taiwan, Elsevier, 1985.
140. Woo SL-Y, Gomez MA, Sites TJ, et al: The biomechanical and morphological changes in the medial collateral ligament of the rabbit after immobilization and remobilization. *J Bone Joint Surg* 69A: 1200-1211, 1987.
141. Woo SL-Y, Gomez MA, Young-Kyun W, Akeson WH: Mechanical properties of tendons and ligaments, II. The relationships of immobilization and exercise on tissue remodeling. *Biorheology* 19: 397, 1982.
142. Woo SL-Y, Matthews JV, Akeson WH, Amiel D, Convery FR: Connective tissue response to immobility: Correlative study of biomechanical measurements of normal and immobilized rabbit knees. *Arthritis Rheum* 18:257, 1975.
143. Wu CC: Posttraumatic Contracture of Elbow Treated with Intraarticular Technique. *Archives of Orthopaedic and Trauma Surgery*. 123(9): 494-500, 2003.
144. Xu Z, Buckley MJ, Evans CH, Sudha A: Cyclic tensile strain acts as an antagonist of IL-1B actions in chondrocytes. *J Immunology* 165:453-460, 2000.
145. Yates CK, McCarthy MR, Hirsch HS, et al: Effects of CPM following ACL reconstruction with autogenous patellar tendon grafts. *J SportsRehab* 1: 121-131, 1992.
146. Zuckerman JD, Leblanc JM, Choueka J, Kummer F: The effect of arm position and capsular release on rotator cuff repair. A biomechanical study. *J Bone Joint Surg Br* 73(3):402-5, May 1991.



Phase I Rehab

1801 Airport Road, Suite D Waukesha, WI 53188

800.845.6364 ~ Phone 888.845.3342 ~ Fax

www.kinexmedical.com