

CONTINUOUS PASSIVE MOTION REHABILITATION AFTER SURGERY FOR GLENOHUMERAL INSTABILITY

Background: Post-operative rehabilitation of the shoulder following glenohumeral instability consists of a period of passive motion to protect the repair, prevent adhesions, prevent the detrimental effects of immobilization, reduce pain, reduce inflammation and promote healing.

Objective: To provide continuous passive motion treatment guidelines after ligamentous and labrum surgery of the shoulder.

Results: Rehabilitation programs following anterior shoulder instability procedures utilizing passive motion provided by a CPM device, a physical therapist, or patient self-directed exercises can be found in the literature. However, no outcome studies on these rehabilitation protocols have been found. Therefore, in light of no unanimity of opinion, rehabilitation programs need to be based on sound principles involving the healing restraints of the surgical procedure and movements that do not stress the suture line. A CPM device is used as the primary passive motion modality because ROM can be performed with the lowest amount of muscle movement and tension on the repair, in the safest range, and in the patients' home resulting in the most cost effective approach.

Conclusion: CPM as the primary passive motion option following anterior shoulder instability repair is a reliable, safe, and a cost effective option.

INTRODUCTION

Rehabilitation for the unstable shoulder continues to evolve with improved surgical stabilization procedures. Currently there is controversy regarding the initial post-operative care (6 weeks) following a glenohumeral instability surgical procedure. One group of clinicians advocate immobilization during the first two weeks while a second group advocates restricted passive motion.^{9, 13,43, 45}

The potential harmful effects of the clinical use of immobilization have been demonstrated by many authors. Although joint immobilization may help protect a certain structure either post-operatively or post-traumatically it has deleterious biological effects on uninjured surrounding soft tissue structures. These findings have led to decreased use of immobilization for soft tissue injuries and have encouraged modalities such as continuous passive motion. Ligaments, for example, have shown to respond to immobilization with alterations that include gross atrophy, loss of ultra structural organization, decreased collagen, and decreased ultimate load bearing and energy absorbing capacity.^{3,15,20,21,31,32,41} Similar alterations have been shown in tendons.^{15,26,41} It has become evident that when joint immobilization is used in the treatment of athletes after injury or surgery, the surrounding uninjured soft tissues undergo biological remodeling. After immobilization, these structures may not be prepared, on a biochemical, biomechanical, or functional basis, to immediately resume the high mechanical demands of athletics.

Wilk et al⁴⁵ after reviewing the treatment of 307 patients following glenohumeral instability surgery determined that patients who were immobilized for 2-4 weeks followed by a rapid progression of therapy to restore ROM had a poorer outcome compared to those who underwent a planned but steady ROM program initiated after surgery. Passive range of motion was typically instituted on the first post-operative day in a restricted arc in order to prevent motion loss or neurological complications.

During the initial healing phase (6 weeks) following glenohumeral instability procedure passive motion exercise is performed to protect the repaired site. The patient may be in a sling when passive motion exercises are not being performed. The degree of protection needed is prescribed by the surgeon and is determined by the type of procedure and quality of the tissue. Protecting the repair does not mean avoiding motion. Post-operative passive motion is utilized in these patients to prevent adhesions, reduce pain, reduce edema, reduce inflammation, and to stimulate soft tissue healing and the potential for easier progression through physical therapy.^{4,13,18,23,28,38,42} The clinical use of complete immobilization post-operatively is avoided to prevent its' potentially harmful effects. Depriving synovial joints and healing tissue of controlled stress after injury may lead to dysfunctional adhesions, disuse atrophy, disuse osteoporosis and weakening of articular cartilage and ligaments.^{2,7,40}

PASSIVE EXERCISE

The principle restraints to anterior translation with the arm positioned in abduction are the superior and the middle glenohumeral ligaments.⁵ Arm elevation to 90 degrees in the scapular plane offers minimal capsule stress. However, elevation above 90 degrees and external rotation stresses the glenohumeral complex. Therefore, following a surgical procedure to prevent excessive anterior translation, passive motion in the scapular plane below 90 degrees is done to avoid stress to the suture line. As healing progresses, gradual stress can be applied into external rotation. Passive motion and other exercises should be performed in the scapular plane up to 6 weeks which prevents undue stress on the healing tissues while influencing tissue remodeling.^{4,42}

Neer et al⁴⁹ developed a general protocol for post-operative care following shoulder surgery that emphasizes early passive motion. The program is divided into three phases depending on the activity of the shoulder musculature: Phase I (passive), Phase II (active), and Phase III (resistive). Prior to the use of CPM, passive motion exercises (Phase I) were typically performed by the patient in their home or in the physical therapy clinic. Patient self-directed exercises consist of wand, over-head pulley or pendulum exercise⁴² (Figure 1). These exercises




Figure 1

Patient self-directed exercises are active or active-assistive exercises and are not performed in the "Tension Free Zone". These exercises are performed in high stress positions outside of the scapular plane which significantly increases tension on the repair.

either utilize the uninvolved extremity to power the involved extremity or the patient attempts to swing the involved extremity in a circular or back and forth motion in a reduced gravity plane. The patient directed exercises were initially developed for rehabilitation following a shoulder joint replacement when precise movement patterns or amount of muscle activity were not critical. However, passive motion exercises following shoulder instability procedures need to be performed in a precise plane of motion with minimal muscle activity or joint strain to protect the suture line⁴.

Modified from Dockery et al¹⁴

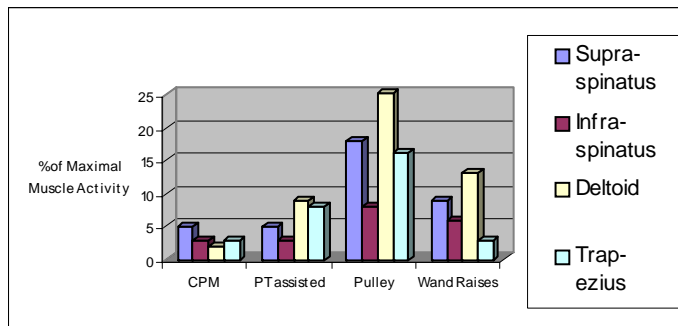


Figure 2

Muscle contraction in healthy shoulders by exercise type. Post-operative shoulders typically have higher contractions than depicted in the graph secondary to post-operative pain and apprehension with the exception of CPM because pain is diminished

Traditional phase 1 exercises (pendulum, pulley, and wand) may not be the most appropriate passive motion option following glenohumeral instability surgery. Electromyography (EMG) studies by Dockery et al⁸ and McCann et al²⁷ demonstrate that CPM exhibited the least amount of muscle movement when compared to self-administered home exercises or PT assisted exercises. Dockery et al⁸ found in all shoulder tested, the pulley exercise exhibited statistically more activity than CPM exercise ($p < .05$). Straight-arm wand raises using the uninvolved arm caused the supraspinatus and deltoid muscles to have significantly more activity ($p < .05$) than CPM. Therapist-assisted elevation in the scapular plane resulted in more deltoid muscle contraction when compared with CPM ($p < .05$). Specific comparisons of

muscle activity in the deltoid muscle by Dockery et al⁸ revealed an average of 25% with the pulley, 11% with the straight-arm wand raises, 8% with therapist assisted elevation and only 2% with CPM; (subjects in this study had healthy shoulder musculature). However, subjects following a surgical procedure would expect to have even higher muscle activity secondary to pain and apprehension.²³ In addition, elbow position appears to add strain to the involved musculature. McCann et al²⁷ showed more muscle activity with the elbow extended during exercise, such as straight arm rises, versus exercise performed with the elbow in a flexed posture. This may be significant in SLAP (superior labrum, anterior and posterior) repairs when the biceps is involved.⁴ Although a direct comparison cannot be made pendulum exercises demonstrated similarly low muscle activity to CPM.^{8,27} However, McCann et al²⁷ reported high inter-subject variability when performing pendulum exercises that were significant for deltoid and spinati musculature. Based on these results, CPM and therapist-assisted passive motion exercise potentially increase the safety boundary in the early post-operative shoulder instability patient, thereby reducing the chance of harmful effects.

Muscle activity is not the only determinant when deciding on the safest and therefore the most appropriate passive exercise. Perhaps even more importantly, passive exercises need to be performed in the scapular plane starting at a position of 30 degrees in abduction. Exercises performed outside of the scapular plane at 0 degrees of abduction or above 90 degrees of abduction and more than 30 degrees of external rotation may apply undue tension to the surgical repair.^{4,11,16,18, 25,28,42,45,48} This is especially true during the initial three weeks following the surgical procedure.^{4,13} Pendulum exercises, wand exercises and over-head pulley exercises have no prevention mechanism to prevent their performance outside of the scapular plane, below 90 degrees or in sub-maximum external rotation. It is unrealistic to expect that unsupervised patient self-directed exercise can be performed within the targeted parameters at all times. This is evident by McCann's et al²⁷ findings of abnormally high inter-subject variability when performing pendulum exercises even under direct supervision.

In contrast, undue tension on the healing repair can be avoided by utilizing a shoulder CPM following a glenohumeral stabilization procedure. The KS2 Shoulder CPM device (available from Kinex, Waukesha WI) can be set to perform elevation separately in a scapular plane (30-90 degrees) followed by separate external and internal rotation all within a safe and precise ROM arc.

THE PHYSIOLOGICAL BASIS OF CONTINUOUS PASSIVE MOTION FOLLOWING LIGAMENTOUS AND LABRAL REPAIR OF THE SHOULDER

Experimental Studies

The clinical use of immobilization may help protect the repaired structure post-operatively but it results in harmful effects on the injured and uninjured surrounding tissue. Soft tissue such as a ligament responds to immobilization with negative alterations including adhesions, gross atrophy, decreased collagen and reduced function.⁴⁶ These findings have led to a decreased use of primarily immobilization and increased use of early mobilization exercises including CPM. In his 23 year review of experimental investigations, Salter⁴⁰ and others have shown the biological benefits of CPM on soft tissue healing of tendon, ligament, and cartilage:

1. The clearance rate of hemiarthrosis in a joint is twice as fast with the use of CPM compared to immobilization which can result in improved tendon and ligament healing.³⁵
2. Significantly thicker tendon callus formation, better alignment of tendon fibers and increased breaking strength in CPM-treated animals following tendon repair.⁴⁰
3. In an experimental model of semitendinosus tenodesis to replace the medial collateral ligament, the CPM-treated animals exhibited significantly stronger healing of the tenodesis. Similar beneficial effects of CPM were seen in an experimental model of medial collateral ligament using carbon fiber.⁴⁷
4. In an investigation of the chondrogenic potential of autogenous osteoperiosteal grafts in a full-thickness defect in a joint surface, it was found that, after 5 weeks, hyaline cartilage was the predominant tissue in only 10% of the immobilized group and the intermittent motion group compared to 70% in the CPM group.³³
5. Wound healing of parapatellar arthrotomy incisions was significantly enhanced by CPM compared to immobilization.⁴⁴
6. Compared with the results in the rabbit treated by immobilization, CPM significantly reduced muscle atrophy in the gastrocnemius muscle as determined from the dry and wet weights.¹⁴

Clinical Studies

More recent research on the post-operative use of shoulder CPM supports Salter's clinical findings on the use of CPM which include the following:

- A. CPM has excellent patient compliance
- B. CPM offers relative freedom from pain
- C. CPM helps maintain and increase ROM
- D. CPM reduces the length of rehabilitation
- E. CPM improves wound healing

Compliance with a home exercise program is a critical concern that should not be overlooked. Milroy²⁹ in a review on compliance of home rehabilitation exercise programs found one-third of patients can be expected to follow through with their prescribed program, another one-third can be expected to comply in part and the final one-third cannot be expected to comply at all. In contrast, home CPM has demonstrated high compliance when compared to non-CPM home programs. Royer³⁹ reported a compliance rate as high as 122% for CPM as participants utilized the device for 7 hours on average which was higher than the 6 hour daily requested rate. High home compliance for CPM programs may be explained by the reduction in pain associated with shoulder CPM use.^{6,10,24,37,39} Lastayo et al²⁹ and Raab et al³⁷ reported statistically significant reductions in pain when CPM was compared to manual passive motion.

Royer et al³⁹, Lastayo et al²³, Gartsmen et al⁵⁰, and Ide et al¹⁸ all demonstrated statistically significant functional ROM with the use of shoulder CPM following shoulder repairs. Raab et al³⁷ found CPM to be superior to manual passive range of motion for regaining ROM following a shoulder surgical procedure.

Royer et al³⁹ found that CPM was equally effective as physical therapy in providing passive motion following a shoulder rotator cuff repair. Because the patient did not have to attend physical therapy as often during the first 6 weeks following the repair a cost savings of \$990 dollars per patient was realized. Similar savings can be expected following glenohumeral surgery which follows a similar post-operative rehabilitation program. Schnebal et al⁵¹ reported that patients “were more comfortable with the use of the machine than without it”. The therapists in this study found as a result that the patients who received CPM had much less discomfort during the physical therapy sessions and seemed to progress more rapidly. Frykman et al⁵² also found that the CPM group following hand surgery showed a more rapid return to both active and passive motion, had less pain, and suffered fewer complications. Herbert et al¹⁷ in a ten year prospective on the use of CPM found that these patients became independent faster and were able to return to work faster than the non-CPM groups.

Adams et al¹ supports Salter’s results concluding that CPM was able to speed wound healing and recovery following hand injuries. In addition Kim¹⁹, Kreder²² and Moran³⁰ have all shown that CPM has reparative effects on inflamed joints. Gassner¹² reported that the molecular basis for CPMs influence on wound healing may be in part due to the application of cyclic tensile stress on the involved joint for an extended time. This tensile stress reduces the effects of the inflammatory process even better than immobilization. O’Driscoll³⁴ theorizes that by speeding the removal of hemiarthrosis from the joint a reduction in adhesions is the result.

SUMMARY

Post-operative rehabilitation following a ligamentous and labral surgery consists of primarily immobilization and passive motion in the scapular plane for 6 weeks to protect the repair. For a growing number of surgeons continuous passive motion has become the preferred passive motion home exercise program. CPM has demonstrated enhanced tendon, ligament and soft tissue healing in contrast to patient self-directed exercises or passive motion by a physical therapist.

CPM is a more true passive motion exercise compared to patient self-directed home pulley, wand or pendulum exercises which decreases the chance that early exercise will jeopardize the repair. CPM ensures that passive motion will be performed in the scapular plane and through a safe arc of motion without stressing the repair. CPM compliance has shown to be higher than other home exercise programs which may be do in part to the pain reduction properties associated with CPM.

CPM has shown in peer-reviewed studies following shoulder surgery to improve and maintain ROM with statistical significance. CPM is the more cost effective alternative compared to physical therapy for providing passive motion. Finally, CPM is well accepted by post-surgical patients and may speed a return to work or pre-injury condition.¹⁷

References:

1. Adams KM, Thompson ST: Continuous passive motion use in hand therapy. *Hand Clinics* 12(1): 109-121, February 1996.
2. Akeson W, Amiel D, Woo S: Immobility effects on synovial joints. The pathomechanics of joint contracture. *Biorheology* 17: 95-110, 1980.
3. Amiel D, Akeson WH, Harwood FL, et al: Stress deprivation effect of metabolic turnover of the medial collateral ligament collagen: A comparison between nine-and twelve-week immobilization. *Clin Orthop* 172: 265-270, 1983.
4. Blackburn TA, Guido JA: Rehabilitation after ligamentous and labral surgery of the shoulder: Guiding concepts. *J Athletic Training* 35(3):373-381, 2000.
5. Bowen MK, Warren RF: Ligamentous control of shoulder instability based on selective cutting and static translation experiments. *Clin Sports Med* 10:757-782, 1991.
6. Craig EV: Continuous passive motion in the rehabilitation of the surgically reconstructed shoulder. A preliminary report. *Orthop. Trans* 10: 219, 1986.
7. Djurasovic M, Aldridge JW, Grumbles R, Rosenwasser MP, Howell D, Ratcliffe A: Knee joint immobilization decreases aggrecan gene expression in the meniscus. *AJSM* 26(3):460-66, 1998.
8. Dockery ML, Wright TW, Lastayo PC: Electromyography of the shoulder: An analysis of passive modes of exercise. *Orthopedics* 21:11, 1998.
9. Ellenbecker TS, Mattalino AJ: Glenohumeral joint range of motion and rotator cuff strength following arthroscopic anterior stabilization with thermal capsulorrhaphy. *J Orthop Sports Phys Ther* 29:160-167, 1999.
10. El-Zahaar MS, Bebars M: The Value Of The Continuous Passive Motion After Repair Of The Rotator Cuff Tear In Athletes (An Arthroscopic Study). *J Neurol Orthop Med Surg* 16:246-252, 1996.
11. Freedman K, Smith A, Romeo A, Cole B, Bach B: Open bankart repair versus arthroscopic repair with transglenoid sutures or bioabsorbable tacks for recurrent anterior shoulder instability. *Amer J Sport Med* 32(6):1520-1527, 2004.
12. Gassner R, Buckley MJ, Georgescu H, Studer R, Stefanovich-Racic M, Plesco NP, Evans CH, and Agarwal S: Cyclic tensile stress exerts anti-inflammatory actions on chondrocytes by inhibiting inducible oxide synthase. *J Immunology* 163:2187-2192, 1999.
13. Gill T, Zarins B: Open repairs for the treatment of anterior shoulder instability. *Amer J Sports Med* 31(1):142-153, 2003.
14. Graham KR, Salter RB: The efficacy of continuous passive motion instituted after surgical release of the post-traumatic persistent elbow: A clinical investigation (abstract). *J Trauma* 29:1301, 1989.
15. Harwood FL, Amiel D: Differential metabolic responses of periarticular ligaments and tendon to joint mobilization. *J Appl Physiol* 72:1687-1691, 1992.
16. Hatakeyama Y, Itoi E, Pradhan RL, Urayama M, Sato K: Effect Of Arm Elevation And Rotation On The Strain In The Repaired Rotator Cuff Tendon: A Cadaveric Study. *Am J Sport Med*, Nov-Dec 2001.
17. Herbert TJ, Fischer WE, Leicester AW: The Herbert bone screw: a ten year perspective. *J Hand Surg* 17B:415, 1992.
18. Ide J, Maeda S, Takagi K: Arthroscopic Bankart repair using suture anchors in athletes. *AJSM* 32(8):1899-1905, 2004.
19. Kim HK, Kerr RG, Cruz TF, Salter RB: Effects of continuous passive motion and immobilization on synovitis and cartilage degradation in antigen induced arthritis. *J Rheumatol* 22(9):1714-21, 1995.
20. Klein L, Heiple KG, Torzilli PA, et al: Prevention of ligament and meniscus atrophy by active joint motion in the non-weight bearing model. *J Orthop Res* 7:80-85, 1989.
21. Klein L, Player JS, Heiple KG, et al: Isotopic evidence for resorption of soft tissues and bone in immobilized dogs. *J Bone Joint Surg* 64A: 225-230, 1982.
22. Kreder HJ, Salter RB, Moran ME: Biological resurfacing of joint defects and cryopreserved allogeneic periosteum stimulated by continuous passive motion. *Orthop Trans* 13:679, 1989.
23. LaStayo PC, Cass R: Continuous passive motion for the upper extremity: why, when, and how. In Hunter JM, et al, editors: *Rehabilitation of the Hand*, ed 5 St Louis, Mosby, 2002.
24. LaStayo PC, Jaffe R: Assessment and management of shoulder stiffness: a biomechanical approach. *J Hand Ther* 7:122, April-June 1994.
25. Levine W, Flatow E: The pathophysiology of shoulder instability. *AJSM*, 2000.
26. Loitz BJ, Zernicke RF, Vailas AC, et al: Effects of short-term immobilization versus continuous passive motion on the biomechanical and biochemical properties of the rabbit tendon. *Clin Orthop* 244:265-271, 1989.
27. McCann PD, Wootten ME, Kadaba MP, Bigliani MD: A kinematic and electromyographic study of shoulder rehabilitation exercises. *Clinical Orthopedics and Related Research* 288: 177-188, March 1993.
28. Merk H, Pap G, Machner A, Nebelung W: Arthroscopic repair of the glenoid labrum using the 3-point knot technique. Early results with consideration to different postoperative immobilization time periods. *Z Orthop Ihre Grenzgeb* 134(6):546-52, 1996.
29. Milroy P: Factors Affecting Compliance to chiropractic prescribed home exercise: A review of the literature. *Journal of the American Chiropractic Association*, Jan 2003.
30. Moran ME, Kim HK, Salter RB: Biologic resurfacing of full-thickness defects in patellar articular cartilage of the rabbit. *J Bone Joint Surg* 74:659, 1992.
31. Newton PO, Woo S.L-Y, Mackenna DA, et al: Immobilization of the knee joint alters the mechanical and ultrastructural properties of the rabbit anterior cruciate ligament. *J Orthop Res* 13:191-200, 1995.
32. Noyes FR, Paulos LE, et al: Intra-articular Cruciate Reconstruction. *Clin Orthop Rel Res* 172, Jan/Feb 1983.
33. O'Driscoll SW, et al: The repair of major osteochondral defects in joint surfaces by neochondrogenesis with autogenous osteoperiosteal grafts stimulated by CPM. *Clin Orthop Rel Res* 208, July 1986.
34. O'Driscoll SW, Giori NJ: Continuous passive motion (CPM): Theory and principles of clinical application. *J Rehab Res Dev* 37: 179, 2000.
35. O'Driscoll SW, Kumar A, Salter RB: The effect of continuous passive motion on the clearance of hemarthrosis from a synovial joint: an experiment investigation in the rabbit. *Clin Orthop* 176:305, 1983.
36. O'Brien JJ, Schwartz RE, Warren RF, Torzill PA: Capsular restraints to anterior/posterior motion of the shoulder. *Orthop Trans* 12:143, 1998.
37. Rabb MG, Rzeszutko D, O'Connor W: Early results of continuous passive motion after rotator cuff repair: A prospective, randomized, blinded, controlled study. *AM J Orthop* 25:214, 1996.
38. Rockwood CA, Matsen FA: *The Shoulder*, Philadelphia, WB Saunders, 1990.
39. Royer C, Kolowich P, Jasper C, Donahue M, Havstad MA: Evaluation and Cost Analysis in use of Continuous Passive Motion After Repair of Rotator Cuff Tears. Unpublished manuscript. Institutional Review Board at Henry Ford Hospital, 2000.
40. Salter RB: The physiologic basis of continuous passive motion for articular cartilage healing and regeneration. *Hand Clin* 10(2):211-9, 1994.
41. Savolainen J, Myllyla V, Myllyla R, et al: Effects of denervation and immobilization on collagen synthesis in rat skeletal muscle and tendon. *Am J Physiol* 254:R897-R902, 1988.
42. Ticker JB: Shoulder Rehabilitation. *AAOS, The Shoulder: Advances in Open and Arthroscopic Techniques*. Orthopaedic Learning Center, Rosemont, IL, October 27-29, 2000.
43. Tyler TF, Calabrese GJ, Parker RD, Nicholas SJ: Electrothermally-assisted capsulorrhaphy (ETAC): a new surgical method for glenohumeral instability and its rehabilitation considerations. *J Orthop Sports Phys Ther* 30:390-400, 2000.
44. Van Royen BJ, O'Driscoll SW, Wouter JAD, Salter RB: Comparison of the effects of immobilization and continuous passive motion on surgical wound healing in the rabbit. *Plast Reconstr Surg* 78:360, 1986.
45. Wilk K, Reingold M, Dugas J, Andrews J: Rehabilitation following thermal assisted capsular shrinkage of the glenohumeral joint: Current concepts. *J Orthop Sports Phys Ther*. 32:268-292, 2002.

46. Woo SL-Y, Gomez MA, Sites TJ, et al: The biomechanical and morphological changes in the medial collateral ligament of the rabbit after immobilization and remobilization. *J Bone Joint Surg* 69A: 1200-1211, 1987.
47. Zarnett R, Valasquez R, Salter RB: The effects of continuous passive motion on knee ligament reconstruction with carbon fibre. *J Bone Joint Surg* 73B:47-52, 1991.
48. Zuckerman JD, Leblanc JM, Choueka J, Kummer F: The effect of arm position and capsular release on rotator cuff repair. A biomechanical study. *J Bone Joint Surg Br* 73(3): 402-5, May 1991.
49. Neer CS, McCann PD, MacFarlane EA, Padilla W: Earlier passive motion following shoulder arthroplasty and rotator cuff repair: A prospective study. *Orthop Trans* 11:231, 1987.
50. Gartsman GMB, O'Connor DP: Arthroscopic rotator cuff repair with and without arthroscopic decompression. *J Shoulder Elbow Surg* 13: 424-6, 2004.
51. Schnebal BE, Evans JP, Flinn D: The use of a passive motion machine for total knee arthroplasty rehabilitation. *Am J Knee Surg* 2(3), July 1989.
52. Frykman GK, et al: CPM improves range of motion after PIP and MP capsulectomies: a controlled prospective study. Abstract 72. Proceedings of the 44th annual meeting of the American Society for Surgery of the Hand, Seattle, September 1989.



Evidence-Based Soft Tissue CPM

1801 Airport Road, Suite D Waukesha, WI 53188
800.845.6364 ~ Phone 888.845.3342 ~ Fax
www.kinexmedical.com